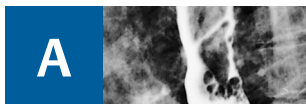


# Index

To view the use of specific modalities in specific clinical conditions, the reader is advised to locate and read the specific conditions. This is because all but the least common imaging or most specialized imaging modalities and techniques are mentioned repeatedly under each clinical condition in the section on "heart disease." References to the modalities in that section, generally, have *not* been included in the index (with certain exceptions where they have *also* been mentioned in the "modalities" section). Under main entries for individual modalities, the reader

will *only* find page references from the "modalities section" (detailing general principles and applications). Under the main entries for specific diseases and conditions the reader will find references to specific modalities, *only* if they have been mentioned in the "modalities" section. Figures and tables are comprehensively referred to from the text. Therefore, significant material in figures and tables has only been given a page reference in the absence of their concomitant mention in the text referring to that figure. "vs" indicates the differential diagnosis of conditions.



**A**

A-mode ultrasound 35

abdominal aorta

- angiography (aortography) 61
- balloon fenestration, intravascular ultrasound 65

acipimox in FDG-PET 72

acoustic quantification 35

- chronic CAD 190

acute aortic syndrome 271-80

acute coronary syndrome, pathogenesis 172-3

adenosine, perfusion MRI 113

- in chronic CAD 190

Agatston calcium score 76, 77, 178, 181

ammonia, <sup>15</sup>N-labelled, for PET 72

amyloidosis 222

Anderson-Fabry disease 224

anesthesia, cardiac catheterization 59

aneurysm

- aortic 267-71
  - imaging 29-30, 86-7, 268-71
- cardiac 22, 198-200, 234, 242
  - radiography 22
  - ventricular 198-200
- coronary, in Kawasaki disease 127
- pulmonary artery 262

angina pectoris 3, 188

- angiography 63, 64
- in aortic stenosis 156
- in mitral stenosis 147
- stable 188
- vasospastic 201

angiocardiology, conventional 59-61

- complications 62
- indications/contraindications 62
- selective 61-2

angiography 59-67

- conventional 59-67
- coronary *see* computed tomographic angiography
- MR *see* magnetic resonance angiography

angioplasty, percutaneous transluminal

- coronary *see* percutaneous balloon transluminal angioplasty

angiosarcoma 234, 238-9

angiосcopy, atherosclerosis and atherosclerotic plaque 173, 176

aorta (thoracic and in general)

- angiography (aortography)
  - conventional 61
  - CT 86-7
  - MR 131-2
- disorders and abnormalities 264-82
  - acquired 265-80

*see also specific abnormalities e.g.*

- aneurysm; coarctation; dissection; sclerosis;
- traumatic aortic injury
  - congenital 28, 88, 264-5

echocardiographic determination, diameter 42

FDG-PET of inflammatory changes 74

intravascular ultrasound, diagnostic and therapeutic use 65

radiography 28-30

aorta angusta 29

aortic sinus (sinus of Valsalva), aneurysm 242

aortic valve 155-61

- bicuspid 161, 267, 272, 275
- in hypertrophic cardiomyopathy 219
- insufficiency/regurgitation 158-61
  - in aortic dissection 275
  - clinical features 159
  - etiology 158
  - imaging 48, 50, 110, 159-61
  - mitral insufficiency combined with 162
  - mitral stenosis combined with 162
  - pathophysiology 158-9
- MRI of normal valve 97
- stenosis 155-8
  - clinical features 156
  - etiology 155
  - imaging 110, 156-8
  - mitral insufficiency combined with 162
  - mitral stenosis combined with 162
  - pathophysiology 155

aortitis 280

aortocoronary bypass grafts 201, 205

apical ballooning syndrome 227

aplasia, pericardial 250-1

arrhythmias 3-4

arrhythmogenic RV dysplasia/cardiomyopathy 23, 215, 225-7

- epidemiology/pathophysiology/clinical features 225-6
- imaging 226-7
- radiography 23

arterial grafts for coronary bypass 201, 203

arterial sclerosis *see* atherosclerosis

arteriovenous malformations, pulmonary 260

MR angiography 132-3

ascending aorta

- anatomy 264
- angiography 61

asymmetric echo, MR angiography of great vessels 128

atheroma 171, 172

atherosclerosis/arterial sclerosis

- aortic 28, 29, 265-7, 277, 278-9
- coronary 171-81
  - imaging 116, 174-81, 174
  - pathogenesis 171-3
  - plaque *see* plaque
  - subclinical signs 171-81

atrioventricular connections, concordant vs discordant, MRI 102-3

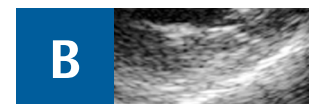
atrium/atria

- enlargement
  - both, in restrictive cardiomyopathy 221
  - LA, radiograph 9-10
  - RA, radiograph 8
- fibrillation, catheter ablation 261
- lymphoma, LA 239
- septum
  - aneurysm 242
  - defect 141-3
  - fatty infiltration/lipomatous hypertrophy 234, 236
- situs 102
- volume, LA, echocardiographic estimation 43

attenuation correction (myocardial scintigraphy) 68

autoregulation, coronary vessels 65-6

axial cine-steady-state free precession 96



**B**

B-mode ultrasound 25

bacterial endocarditis *see* endocarditis

balloon dilatation, percutaneous *see* percutaneous balloon transluminal angioplasty

balloon fenestration of abdominal aorta, intravascular ultrasound 65

Behçet disease 252

bicuspid aortic valve 161, 267, 272, 275

bioprosthetic valves 166, 168

biopsy, endomyocardial *see* endomyocardial biopsy

biventricular pacing in dilated cardiomyopathy, echocardiographic criteria 216-17

blood flow/pressure *see* flow; pressure

bolus timing, contrast-enhanced MRA of great vessels 130

brachial artery approach to coronary angiography 63

breathing in MR coronary angiography

- breath-hold 121, 123-4
- free 124

breathlessness (dyspnea) 3

bright-blood sequences (MRI) 92

- morphological imaging 98

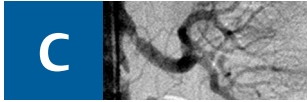
"bright is dead" rule 196

broadband scattering 34

bronchial artery position in atrial situs 102

bronchial carcinoma invading pulmonary arteries 261-2

bypass grafts in CAD 201-8



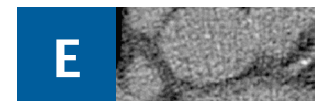
C-reactive protein test 180  
 calcifications  
   cardiac, radiography 5, 6  
   coronary 171  
     intravascular ultrasound 65  
     stented vessel 209  
 calcium, coronary 171  
   determination 76-8, 81  
 cancer *see* malignant tumors  
 capillary hemangioma, pulmonary 259-60  
 carcinoma, bronchial, invading pulmonary arteries 261-2  
 cardiac disease and function *see* heart disease and specific functional parameters *e.g.*  
   ejection fraction; output; rate  
 cardiomyocytes in chronic CAD 188  
 cardiomyopathies 215-27  
   dilated *see* dilated cardiomyopathy  
   hypertrophic *see* hypertrophic cardiomyopathy  
   infiltrative 222-4  
   radiography 22-3  
   restrictive *see* restrictive cardiomyopathies  
   unclassified and secondary 23, 215, 216, 227  
 catheter ablation, atrial fibrillation 261  
 catheterization  
   for angiocardiology 59-62  
   for intravascular ultrasound 64  
 chambers, cardiac  
   enlargement *see* enlargement  
   radiographs 5-10  
 chest pain  
   aortic syndrome (incl. dissection) 271, 272  
   differential diagnosis 3  
   ischemic/cardiac *see* angina pectoris  
 Chiari network 242  
 chordae tendinae rupture 150  
 cine sequences, ventricular aneurysm 199  
 cine steady-state free precession (SSFP)  
   sequence 100  
   axial 96  
 clinical manifestations of heart disease 3-4  
 coarctation, aortic 28-9, 265  
   MR angiography 131-2  
 coherent motion in tissue Doppler echocardiography 45  
 collateral vessels in myocardial ischemia and infarction 181-3  
 collimation, CT coronary angiography 81  
 color Doppler 45  
   transmitral inflow 47  
 color kinesis 35  
   chronic CAD 190, 195  
 computed tomographic angiography  
   coronary vessels 80-4  
   great vessels 84-8  
   renal failure contraindicating 254  
 computed tomography 76-90  
   multislice *see* multislice spiral CT  
   pericardial 243  
   principles 80  
   *see also* positron emission tomography/CT  
 concordant motion in tissue Doppler echocardiography 46  
 congenital cardiovascular anomalies (and congenital heart disease) 101-2, 141-6  
   aorta 28, 88, 264-5  
   CT angiography  
     coronary vessels 84  
     great vessels 88  
   MR angiography  
     coronary vessels 126  
     great vessels 131-3  
   MRI 101-2  
   pulmonary vessels 260-1

radiography, great vessels (incl. aorta) 28  
 tumors vs 242  
 congestion, pulmonary 12, 18, 21  
 consent, informed  
   cardiac catheterization 59  
   CT coronary angiography 80  
 constrictive pericarditis 27, 247-50  
   anatomy/pathophysiology/clinical features 247  
   hypertrophic cardiomyopathy vs 221  
 continuity equation 50  
 continuous-wave Doppler 44  
 contractility (myocardial)  
   in ischemia 180-1  
   LV, echocardiographic assessment 52  
 contrast echocardiography 37  
 contrast mechanisms in MRI  
   in coronary MR angiography 124-5  
   with pathological 98  
 contrast media/agent  
   conventional angiography, test injection 60  
   CT angiography of coronary vessels 81  
     adverse events 80  
   CT angiography of great vessels 84, 85  
   echocardiography 37  
   MR angiography  
     coronary vessels 125-6  
     great vessels 129-30  
   MRI 113  
     administration in delayed-enhancement imaging 120  
 contrast radiography, esophagus 5  
 cor pulmonale 15-16, 25  
 coronary angiography  
   conventional 63-4  
   CT 80-4  
   MR 121-7  
 coronary angioplasty *see* percutaneous balloon transluminal angioplasty  
 coronary artery  
   aneurysms in Kawasaki disease 127  
   angiography *see* coronary angiography  
   anomalies *see* congenital cardiovascular anomalies  
   atherosclerosis *see* atherosclerosis  
   calcium *see* calcifications; calcium plaque *see* plaque  
   stenosis *see* stenosis  
 coronary artery disease (CAD; coronary heart disease; CHD) 22-3, 171-214  
 chronic (incl. chronic myocardial ischemia and late sequelae of MI) 187-201  
   cardiomyopathy in 217  
   clinical features 188  
   diagnosis 188-200  
   pathophysiology 187  
 early detection 171  
 imaging 171-214  
   CT angiography 83-4  
   Doppler intravascular ultrasound 65-6  
   intravascular ultrasound 65, 174, 193  
   myocardial scintigraphy 70-1  
   postoperative and postinterventional 201-10  
   radiography 22-3  
   prevention 176-81  
   *see also* acute coronary syndrome  
 coronary stent 201, 208-10  
 crista terminalis 242  
 cross-sectional area of valve orifice 50  
 cyanosis 3  
 cysts, pericardial 244-5



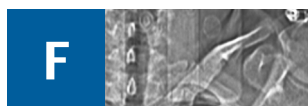Dallas criteria 227  
 dark-blood sequences (MRI) 92

morphological imaging 98, 99  
 DeBakey classification of aortic dissection 30, 271, 272  
 degenerative disorders/change  
   aorta 265-71  
   aortic valve 155, 158  
   mitral valve 150, 154  
 delay time, myocardial return to start position in MRI 99, 100  
 delayed-enhancement MRI *see* late enhancement MRI  
 descending (thoracic) aorta  
   anatomy 264  
   dissection (=type B) 271, 272, 273, 274-5  
   right 28, 264  
 dextrocardia, mirror-image 17  
 dextroposition 17  
 dextroversion 17  
 diabetes, myocardial scintigraphy 71  
 diameter  
   cardiac *see* size  
   coronary stent 209  
 diastole  
   echocardiographic studies in  
     pulmonary arterial pressure 51  
     ventricular function/dysfunction 54-5  
   in restrictive cardiomyopathy, severe dysfunction during 221  
 dilatation *see* enlargement  
 dilated cardiomyopathy 23, 24, 215, 215-18  
   epidemiology/pathophysiology/clinical features 215-16  
   imaging 216-18  
     radiography 23, 24  
 dipyridamole, perfusion MRI 113  
 in chronic CAD 193  
 dissection, aortic 30, 271  
   CT angiography 86-7  
   intravascular ultrasound 30  
   radiography 30  
   traumatic *see* traumatic aortic injury  
 diverticula, pericardial 244-5  
 dobutamine stress  
   in chronic CAD 188-9, 191, 194, 195-6  
   echocardiography 38  
   MRI 107  
   perfusion studies 113  
 Doppler ultrasound  
   heart (Doppler echocardiography) 44-7  
   hemodynamic assessment 48, 49, 50  
   reference values 46  
   systolic LV function 52  
   intracoronary 65-6  
   tissue *see* tissue Doppler  
 double aortic arch 28, 264  
 double-disk valves 166, 168, 169  
 double-oblique sections of the heart (MRI) 92  
 dual-source CT 80  
 DuBois formula 104  
 dyskinesia, ventricular aneurysm 198, 199  
 dyspnea 3  
 dysrhythmias 3-4



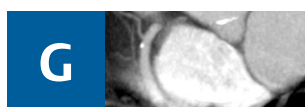ECG *see* electrocardiography  
 echocardiography 34-58  
   basic principles 34-6  
   examination techniques 40-2  
   pericardial 243  
   quantification using 41-3  
   specific applications 37-40  
 Echovist-300 37  
 edema 3  
   myocardial (ischemic-reperfused myocardium) 184  
   pulmonary, in chronic heart failure 18

effusions  
 pericardial 25, 26, 27, 245, 246  
 in aortic dissection 275  
 imaging 27, 243, 244, 246, 247  
 pleural *see* pleural effusions  
 ejection fraction, MRI determination 104  
 electrocardiography (ECG)  
 in CT angiography  
 coronary vessels 81  
 great vessels 86  
 in MRI 91  
 ECG-triggered sequences 105, 105-6  
 sarcoidosis 223  
 electrocardiography-gated myocardial scintigraphy 68-9  
 electron beam CT of coronary vessels 80, 180  
 calcium determination 76-8  
 elongation, aortic 29  
 emboli, pulmonary 21, 252-6  
 acute 252-5  
 clinical classification 252  
 clinical features 252  
 diagnosis 252  
 pathophysiology 252-3  
 risk factors 252  
 chronic recurrent 20, 21, 255-6  
 imaging 253-5  
 CT angiography 87-8, 253-4  
 radiography 20, 21  
*see also* microemboli; thromboembolic  
 pulmonary hypertension, chronic  
 endocardial tumors 232  
 endocarditis (infective/bacterial)  
 aortic valve 160  
 mitral valve 152  
 prosthetic valve dysfunction 166, 169  
 endocrine causes of hypertension 24  
 endomyocardial biopsy  
 cardiomyopathies 215  
 sarcoidosis 223  
 myocarditis 227  
 endomyocardial disease 224-5  
 enlargement/dilatation  
 aorta 29  
 chambers 5-10  
 atria *see* atrium  
 diseases leading to 11, 18, 20  
 radiographs 5-10, 11  
 enzyme replacement therapy in Anderson–  
 Fabry disease 224  
 esophagus  
 contrast radiography 5  
 echocardiography via 39, 40-1  
 EuroSCORE 181  
 exercise stress imaging  
 echocardiography 38  
 MRI 107  
 perfusion studies 113



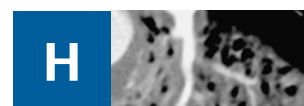
failure, heart 17-21  
 acute 17, 20  
 causes 13, 17  
 chronic 17-21  
 causes 12, 17  
 radiography 17-21  
 global 21  
 left 19  
 right 20  
 fast low-angle shot (FLASH) MRI 105, 106  
 fast spin-echo sequences *see* turbo spin-echo  
 sequences  
 fat suppression  
 MR coronary angiography 125  
 MRI 98

fatty infiltration (lipomatous hypertrophy) of  
 atrial septum 234, 236  
 fatty streaks 171, 172  
 FDG *see* fluorodeoxyglucose  
 females with coronary heart disease, myocar-  
 dial scintigraphy 71  
 femoral artery catheterization  
 coronary angiography 63  
 intracardiac angiography 59-60  
 fibrinous pericarditis 26, 245  
 fibroatheroma 171  
 fibroelastoma 233, 236  
 fibroma 233, 238  
 fibrosis  
 endomyocardial 225  
 pericardial, in constrictive pericarditis  
 247  
 Fick method, cardiac output measurement  
 60, 61  
 filling pressures, LV, echocardiographic studies  
 50, 55-6  
 first-pass perfusion MRI 112  
 FLASH MRI 105, 106  
 flow (blood)  
 in coronary bypass graft 206  
 Doppler echocardiography studies 44, 45  
 reference values for flow velocity 46, 47  
 Doppler studies in coronary vessels 65-6  
 MRI  
 flow compensation 105  
 measurement 108-9  
 regional myocardial flow as indicator of  
 perfusion 111  
 pulmonary, decreased 15  
 shunt, echocardiographic studies 49  
 fluorodeoxyglucose (FDG)-PET 71-2, 72  
 hibernating myocardium 73, 195  
 plaque imaging 73, 74  
 fluoroscopy, preliminary 5  
 foramen ovale, patent 143-4  
 four-chamber view (MRI) 94  
 Fourier techniques, MR angiography of great  
 vessels 128  
 fractional echo, MR angiography of great  
 vessels 128  
 fractional flow reserve (FFR), myocardial 66  
 Framingham Study 176, 181  
 free-breathing in MR coronary angiography  
 124  
 frequency-encoding direction, MR angiography  
 of great vessels 128  
 frontal radiograph *see* posteroanterior radio-  
 graph

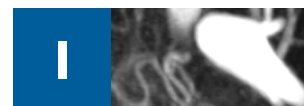

gadolinium (paramagnetic)-enhanced MR  
 studies 113  
 late *see* late enhancement MRI  
 MR angiography  
 coronary 125-6  
 great vessels 129-30  
 gamma cameras for SPECT 68  
 gastroepiploic artery for coronary bypass 203  
 gated myocardial scintigraphy 68-9  
 gelatin solution in contrast echocardiog-  
 raphy 37  
 glucose metabolism, myocardial 72  
 gradient-echo (GE) sequences 92  
 coronary bypass 203  
 functional imaging 105, 106-7  
 great vessels 128  
 intracardiac thrombi 241  
 great vessels 252-63  
 CT angiography 84-8  
 MR angiography 127-33  
 guidewire

cardiac catheterization 59  
 intracoronary Doppler 65



heart disease (in general)  
 clinical manifestations 3-4  
 pulmonary vascular pressure changes due to  
 12  
*see also specific types of disease/disorders/  
 dysfunction e.g.* arrhythmias; coronary heart  
 disease; failure  
 heart function/physiology *see specific paramet-  
 ers e.g.* ejection fraction; output; rate  
 Heinz–Nixdorf Recall Study 180  
 helical CT *see* spiral CT  
 hemangioma  
 cardiac 233, 237  
 pulmonary vascular 259-60  
 hemochromatosis, cardiac 216  
 hemodynamics 48-51  
 coronary, Doppler studies 65, 66  
 echocardiographic assessment 48-51  
 pulmonary  
 pulmonary vascular changes due to  
 alterations in 13  
 radiography 11-12  
 in restrictive cardiomyopathies 221  
 hemorrhage or hematoma  
 aortic intramural 277  
 coronary plaque 172, 173  
 heterotaxy syndrome 102  
 histology, virtual, atherosclerotic plaque  
 175-6  
 history-taking, coronary CT angiography 80  
 horizontal long axis of LV (MRI) 94  
 Hounsfield units/scale 80  
 Hughes–Stovin syndrome 252  
 hyperemia, pulmonary 15  
 hypereosinophilic syndrome 225  
 hyperplasia of atrial septum, fatty 234  
 hypertension 3, 23-5  
 pulmonary arterial *see* pulmonary arterial  
 hypertension  
 systemic/arterial 4, 23-5  
 hypertrophic cardiomyopathy 23, 215, 218-21  
 epidemiology/pathophysiology/clinical  
 features 218  
 imaging 23, 218-21  
 obstructive 215, 218, 219  
 hypertrophy  
 atrial septum, lipomatous (=fatty deposits)  
 234, 236  
 ventricular 11  
 hypoplasia of aortic arch, congenital 264  
 hypotension, cardiac 4



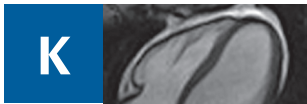incoherent motion in tissue Doppler echocar-  
 diography 45  
 indium-111-labelled monoclonal antibody,  
 myocarditis 229  
 inertial mass 50  
 infections  
 endocardial *see* endocarditis  
 myocardial 228, 229  
 inflammatory activity, reperfused myocardium  
 184  
 inflammatory aortic disease 280  
 inflow tract of ventricles, MRI  
 LV 95  
 positional anomalies 102



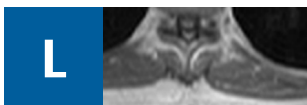
informed consent *see* consent  
 integrated scatter 34-5  
 interstitial pulmonary edema 18  
 intima  
   tear and flap in aortic dissection 272, 273, 274, 274-5, 275  
   thickening 171, 172  
     detection 65, 180  
 intracardiac echocardiography 39-40  
 intracardiac pressure evaluation  
   catheterization techniques 60  
   echocardiographic techniques 50-1  
   *see also* ventricles  
 intracardiac shunts *see* shunts  
 intraoperative echocardiography 39  
 intravascular ultrasound 64-6  
   CAD 65, 174, 193  
   myocardial bridging *see* myocardium  
 invasive imaging techniques 64-6  
   coronary artery disease, review of 174  
 inversion (and situs inversus), cardiac  
   MRI 101-2  
   radiography 17  
 inversion pulse (MRI)  
   delayed-enhancement imaging 117, 118  
   morphological studies 98, 99  
   perfusion studies 112  
 inversion-recovery sequences 117, 120  
   in coronary MR angiography 125-6  
   of intracardiac thrombi 241  
   phase-sensitivity 118  
 inversion time  
   delayed-enhancement imaging 118  
   perfusion MRI 112  
 iodine concentration of contrast medium in CT  
   coronary angiography 81  
 ischemia, myocardial *see* myocardial ischemia  
 ischemic cardiomyopathy 217



Judkins technique 63

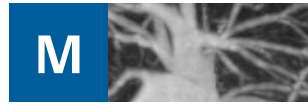

Kawasaki disease, coronary MR angiography 127  
 Kerley A and B lines 19  
 kidney *see entries under* renal



late (delayed) enhancement MRI 116-21  
   hypertrophic cardiomyopathy 219-20  
   infiltrative cardiomyopathies  
     amyloidosis 222  
     sarcoidosis 223-4  
   myocardial hibernation 194-5  
   myocardial scar/chronic infarction 196  
   myocarditis 229-30  
 lateral radiograph 4-5  
   atrial enlargement, right 9  
   ventricular enlargement  
     left 8  
     right 6  
 leiomyosarcoma, pulmonary vascular 256-9  
 Levovist 37  
 lipoma 233, 234-6  
 lipomatous (fatty) infiltration of atrial septum 234, 236

liposarcoma 238  
 local anesthesia, cardiac catheterization 59  
 Löffler syndrome 225  
 lumen in aortic dissection  
   false 272, 274  
   true 274  
 Luminiti 37  
 lungs  
   carcinoma invading pulmonary arteries 261-2  
   congestion 12, 18, 21  
   edema in chronic heart failure 18  
   perfusion mapping with CT 254  
 lymphangioma 233, 238  
 lymphatic system 16  
 lymphoma, primary 234, 239



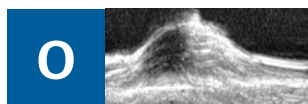
M-mode echocardiography 35  
   color Doppler 45  
   LV function 51  
   quantification using 41  
 magnetic resonance angiography 121-33  
   coronary arteries 121-7  
   great vessels 127-33  
 magnetic resonance imaging 91-137  
   clinical applications 110  
   function 104-10  
   gradient-echo *see* gradient-echo sequences  
   morphology 98-103  
   pericardial 243-4  
   planning the examination 91-7  
   spin-echo *see* spin-echo sequences  
 malignant tumors  
   cardiac 232, 238-40  
     MRI signal characteristics 234  
     pericardial 238-9, 239-40, 240, 250  
     secondary *see* metastases  
   pulmonary vascular 256-9, 261-2  
 malposition  
   MRI 101-2  
   radiography 17  
 mammary artery, internal, for coronary bypass 201, 203  
 mass (pathological lump)  
   neoplastic *see* tumors  
   nonneoplastic 240-2  
 mass (physical quantity)  
   calcium, determination 77-8  
   myocardial *see* myocardium  
 maximum intensity projection, contrast-enhanced MR angiography 130  
 mechanical heart valves 166, 167  
 medial thickening 180  
 mesothelioma, pericardial 234, 239-40  
 metabolism, ischemic myocardium 180-1  
 metaiodobenzylguanidine (MIBG) scintigraphy 73  
 metastases, cardiac 232, 234, 240  
   pericardium 240, 250  
 MIBG scintigraphy 73  
 microemboli, coronary 176  
 mirror-image dextrocardia 17  
 mitral valve 147-54  
   annulus velocity, Doppler studies 46-7  
   defects (in general) 147-54  
     radiography 9  
   flow velocity, Doppler studies 46, 47  
   in hypertrophic cardiomyopathy 219  
   insufficiency/regurgitation 150-4  
     aortic insufficiency combined with 162  
     aortic stenosis combined with 162  
     etiology 150  
   imaging 49, 50, 110, 152-4  
     pathophysiology 150-1  
   MRI of normal valve 96, 97

orifice area, echocardiography studies 49, 50  
 prolapse 150, 151  
 prosthetic 168, 169  
 stenosis 147-50  
   aortic insufficiency combined with 162  
   aortic valve insufficiency combined with 162  
   clinical features 147  
   echocardiographic studies 49, 50, 148-9  
   etiology 147  
   insufficiency accompanying 151  
   MRI 250  
   pathophysiology 147  
   radiography 9  
 motion  
   cardiac/ventricular wall  
     in acute ischemia 186  
     in arrhythmogenic right ventricular cardiomyopathy 226  
     artifacts due to, CT coronary angiography 82  
     in chronic ischemia 189, 198  
     compensation in MR coronary angiography for 122  
     echocardiographic studies 52-4  
     MRI studies 104-7, 186  
     with ventricular aneurysm 198  
   respiratory, compensation in MR coronary angiography for 123-4  
 multiplanar reformation 82  
 pulmonary embolism 254  
 multislice spiral (helical) CT  
   coronary vessels 80  
     bypass grafts 202-3  
     calcium determination 78-9  
     in chronic CAD 193, 200  
     stents 208, 209-10  
   great vessels 86  
 mural thrombosis 173  
 myocardial infarction 181  
   delayed-enhancement MRI, acute and chronic MI 120  
   infarct size and its determinants 181-3  
   late sequelae *see* coronary artery disease, chronic  
   radiography (acute and chronic) 22  
 myocardial ischemia 181-201  
   acute 181-6  
     pathophysiology 181-3  
   chronic *see* coronary artery disease, chronic  
   imaging 181-6  
     perfusion MRI 114, 186  
   reperfusion following *see* reperfusion  
   review of invasive and noninvasive tests 174  
 myocarditis 227-30  
   epidemiology/pathophysiology/clinical features 227-8  
   imaging 228-30  
 myocardium  
   bridging 201  
     intravascular ultrasound 65, 66, 201  
   contractility *see* contractility  
   edema (ischemic-reperfused myocardium) 184  
   fractional flow reserve (FFR<sub>myo</sub>) 66  
   hibernation 184, 187, 194-5, 200  
     imaging 73, 194-5, 195  
   mass determination 104  
     LV, echocardiographic estimation 41  
   metabolism in ischemia 180-1  
   metastases 240  
   motion *see* motion  
   perfusion *see* perfusion; reperfusion  
   primary disease *see* cardiomyopathies  
   scar 185, 188, 195-8, 200  
     imaging 73, 195-8, 198  
   scintigraphy *see* scintigraphy  
   strain 47  
   stunning 184, 194


tagging 107-8  
 viability, assessment 71, 72, 73, 184, 198  
 wall *see* wall  
 myxoma 233-4



neoplasms *see* tumors  
 neurocardiogenic stunning 227  
 nitrogen-15-labelled ammonia for PET 72  
 nuclear medicine 68-75  
 chronic CAD 193, 195  
 Nyquist limit 44




oblique views, technique 5  
 obstructive hypertrophic cardiomyopathy 215, 218, 219  
 offline reconstruction in 3D echocardiography 35-6  
 optical coherence tomography 173  
 Optison 37  
 osteosarcoma 238  
 ostium primum 141  
 ostium secundum 141  
 outflow tract  
 LV  
 Doppler studies of flow velocity 46  
 echocardiographic studies of gradient across 51  
 MRI 95  
 obstruction in hypertrophic cardiomyopathy 215, 218, 219  
 RV, MRI 97  
 output, cardiac  
 cardiac catheterization assessment 60-1  
 echocardiographic assessment 48  
 oxygen saturation measurements, catheterization methods 60  
 oxygen-15-labelled water for PET 72



pacing in dilated cardiomyopathy, echocardiographic criteria 216-17  
 pain, chest *see* chest pain  
 papillary fibroelastoma 233, 236  
 papillary muscle rupture 150, 152  
 parallel imaging  
 MR angiography of great vessels 129  
 MRI 113  
 paramagnetics in MRI *see* gadolinium  
 partial anomalous pulmonary venous drainage 261  
 partial (fractional) echo, MR angiography of great vessels 128  
 percutaneous approach to cardiac catheterization 59  
 percutaneous balloon transluminal angioplasty (PTCA) 201  
 with stent 201, 208-10  
 perfusion, myocardial 111-16  
 assessment 111-16, 186  
 in chronic CAD 191, 191-3  
 MRI 111-16, 186, 191-3  
 nuclear imaging 71, 72, 72-3  
 physiology 111-12  
*see also* reperfusion

perfusion, pulmonary, CT imaging 254  
 pericarditis 25, 26, 245-7  
 constrictive *see* constrictive pericarditis  
 pathophysiology and clinical features 25, 26, 245-6  
 pericardium 25-7, 243-51  
 anatomy 243  
 effusions *see* effusions  
 imaging modalities 243-4  
 non-neoplastic disorders 244-50, 250-1  
 tumors 232, 250  
 angiosarcoma 238-9  
 lymphangioma 238  
 mesothelioma 234, 239-40  
 metastases 240, 250  
 teratoma 238  
 PET *see* positron emission tomography  
 pharmacological stress imaging  
 in chronic CAD 188-9, 191, 193, 194, 195-6  
 echocardiography 38  
 MRI 107  
 perfusion studies 113  
 myocardial scintigraphy 68  
 phase-sensitive inversion-recovery sequences 118  
 pheochromocytoma 233, 237  
 pigtail catheter, angiography 59  
 PISA method *see* proximal isovelocity surface area  
 plain films *see* radiography  
 planimetry, aortic valve 157  
 plaque, atherosclerotic  
 aortic 277, 278  
 coronary vessels and in general  
 complicated 172-3, 175-6  
 CT angiography 84  
 FDG-PET 73-4  
 formation 171, 172, 172-3  
 intravascular ultrasound 65, 175, 177  
 other imaging methods 175-6  
 rupture 172-3, 175-6  
 rupture susceptibility of unstable/vulnerable plaques 176  
 pleural effusions 16-17  
 in aortic dissection 275-6  
 pericardial effusions vs 243  
 positional abnormalities *see* malposition  
 positron emission tomography (PET) 71-3  
 basic principles 68  
 myocardial scar 198  
 plaque imaging 73  
 positron emission tomography/CT (PET/CT), plaque 74  
 posteroanterior (frontal radiograph) 4  
 atrial enlargement, right 8  
 technique 5  
 ventricular enlargement  
 left 6-8  
 right 5-6  
 postoperative imaging, CAD 201-8  
 pressure (blood)  
 abnormal *see* hypertension; hypotension  
 gradients, echocardiographic studies 49  
 half-time, echocardiographic studies 49  
 intracardiac *see* intracardiac pressure; ventricles  
 intracoronary 65-6  
 Doppler studies 65-6, 66  
 transstenotic 66  
 pulmonary arterial *see* pulmonary arteries  
 pressure overload 11  
 causes 12  
 right-side heart failure due to 20  
 pressure wire, intracoronary 66  
 preventive cardiology (CHD prevention) 176-81  
 PROCAM (Prospective Cardiovascular Munster Heart) study and score 176, 181  
 prosthetic valves 166-9  
 proximal isovelocity surface area (PISA) method 48-9

mitral valve orifice area 153  
 mitral valve prosthesis 169  
 pseudoaneurysm of aorta 267  
 pseudocoarctation of aorta 265  
 PSIR sequences 118  
 pulmonary angiography  
 conventional 62  
 MR 130, 132-3  
 pulmonary arterial hypertension 252, 256  
 with atrial septal defect 142  
 chronic thromboembolic *see* thromboembolic pulmonary hypertension, radiography 11, 15-16, 25  
 pulmonary arteries 252-6  
 bronchial carcinoma invasion 261-2  
 disorders 252-6  
 aneurysms 262  
 embolism *see* emboli  
 sarcomas (PAS) 256, 257  
 position in atrial situs 102  
 pressure  
 echocardiographic calculation 51  
 high *see* pulmonary arterial hypertension  
 pulmonary capillary wedge pressure measurement 60  
 pulmonary non-vascular problems *see* lungs  
 pulmonary valve  
 combined disease of tricuspid and 165  
 insufficiency 165  
 MRI 110  
 MRI of normal valve 97  
 stenosis 165  
 pulmonary veins  
 disorders 260-1  
 congestion 12, 18, 21  
 sarcomas (PVS) 256, 257  
 flow velocity, Doppler studies 46  
 incompletely opacified (in CT angiography), vs pulmonary embolism 254  
 pulmonary vessels (in general) 252-63  
 angiography *see* pulmonary angiography  
 disorders 252-63  
 neoplastic 133, 256-60, 261-2  
 radiography 11-16  
 pulsation artifacts, CT angiography of great vessels 86  
 pulse sequences  
 MR angiography  
 coronary 123  
 great vessels 128-9  
 MRI 91-2  
 delayed-enhancement imaging 117-19  
 functional imaging 105  
 morphological imaging 98  
 perfusion imaging 112-13  
 pulsed Doppler 44

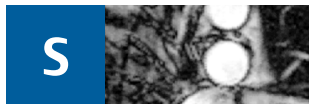


qualitative perfusion MRI analysis 114-15  
 quantitative perfusion MRI analysis 116



R wave, MRI and 99  
 radial artery approach to coronary angiography 63  
 radiofrequency (RF) ablation, atrial fibrillation 261  
 radiofrequency (RF) data, tracking in 47  
 radiography, conventional (plain films/X-rays) 3-33  
 anatomy 4-33

pericardial 243  
 technique 5  
 radionuclide imaging *see* scintigraphy; single-photon emission computed tomography  
 radiotracers  
 myocardial scintigraphy 69-70  
 PET 72-3  
 rate, heart, CT coronary angiography 80-1  
 regurgitant volume  
 in aortic insufficiency 158, 161  
 in aortic stenosis 155  
 echocardiographic assessment 48-9  
 in mitral valve insufficiency 150, 151, 153, 154  
 remodelling in coronary atherosclerosis 171-2  
 negative 172, 177  
 positive 172, 177  
 renal disorders, hypertension due to 24  
 renal failure, CT angiography contraindicated in 254  
 reperfusion 184  
 injury on 183, 184  
 repetition times (TR) 98  
 MR angiography of great vessels 128  
 respiratory artefacts vs pulmonary embolism (on CT angiography) 254  
 respiratory distress (dyspnea) 3  
 respiratory motion in MR coronary angiography, compensation angiography for 123-4  
 re-stenosis with coronary stents 208, 209  
 restrictive cardiomyopathies 23, 215, 221-5  
 imaging 221-2  
 radiography 23  
 resynchronization therapy in dilated cardiomyopathy, echocardiographic criteria 216-17  
 revascularization procedures 201-10  
 rhabdomyoma 233, 237  
 rhabdomyosarcoma 234, 240  
 rheumatic fever 147  
 risk factors for CHD, preventive strategies related 176-81  
 rubidium-82 for PET 72-3



saline, contrast echocardiography 37  
 sarcoidosis 222-4  
 sarcomas  
 cardiac 238-9  
 MRI signal characteristics 234  
 pulmonary vascular 256-9  
 saturation time, perfusion MRI 112  
 scar  
 myocardial *see* myocardium  
 pericardial, in constrictive pericarditis 247  
 scatter/scattering  
 broadband 34  
 integrated 34-5  
 scintigraphy, myocardial 68-71  
 myocarditis 228, 229  
 sclerosis, arterial *see* atherosclerosis  
 screening, CHD risk levels 176-81  
 semiquantitative analysis of perfusion MRI images 115  
 septum  
 atrial *see* atrium  
 cardiac catheterization across 59  
 ventricular *see* ventricles, septal defect  
 sestamibi 69, 70  
 shock, cardiogenic, causes 13  
 short-axis views (MRI) 92-4  
 shunts  
 intracardiac  
 angiographic detection 61  
 echocardiographic studies of flow 49  
 MRI studies 110

pulmonary arteriovenous 260  
 signal-to-noise (SNR) ratio in MRI 91  
 MR angiography of great vessels 128  
 myocardial perfusion studies 112  
 signs and symptoms of heart disease 3-4  
 single-photon emission computed tomography (SPECT)  
 basic principles 68  
 hibernating myocardium 195  
 myocardial 68-9  
 single-shot IR-SFFP sequences 118-19  
 single-shot turbo spin-echo (TSE) sequences 100  
 coronary bypass 204  
 single-slice image acquisition 77  
 sinus of Valsalva, aneurysm 242  
 sinus rhythm for CT coronary angiography 80-1  
 sinus venosus 141  
 situs ambiguus 102  
 situs inversus *see* inversion  
 size (incl. diameter), cardiac  
 echocardiographic determination 42  
 LV 51  
 radiographic determination 10  
 small-disk summation method 199  
 software, MR angiography of great vessels 128  
 Sonos method 63  
 SonoVue 37  
 SPAMM 107  
 spatial modulation of magnetization (SPAMM) 107  
 speckle tracking 47, 47-8  
 SPECT *see* single-photon emission computed tomography  
 spin-echo (SE) sequences 92  
 coronary bypass 204  
 morphological imaging 98  
 spiral (helical) CT  
 great vessels 84  
 multislice *see* multislice spiral CT  
 spoiled sequences, great vessels 128  
 SSFP *see* steady-state free precession  
 Stanford classification of aortic dissection 30, 271, 272  
 steady-state free precession (SSFP) sequence 100  
 cine *see* cine steady-state free precession  
 of coronary bypass 203-4  
 coronary MR angiography 125  
 functional imaging 106-7  
 morphological imaging 96, 100  
 single-shot IR- 118-19  
 steal phenomenon, coronary bypass graft stenosis 206  
 stenosis  
 coronary 200-1  
 CT angiography 83  
 differential diagnosis 200-1  
 Doppler studies 65, 66  
 myocardial scintigraphy 70  
 coronary bypass graft 201, 202, 203, 205, 206, 207, 208  
 pulmonary vein, complicating catheter ablation in atrial fibrillation 261  
 valvular, MRI 110  
*see also specific valves*  
 vascular (in general), MRI 110  
*see also re-stenosis*  
 stent, coronary 201, 208-10  
 stent-graft, aortic, intravascular ultrasound for implantation of 65  
 stethoscope, ultrasound 36  
 strain rate imaging 47  
 chronic CAD 190, 195  
 stress cardiomyopathy 227  
 stress imaging  
 in chronic CAD 188, 188-9, 189-90, 191, 193, 194, 195-6  
 echocardiography 38  
 wall-motion abnormalities 53, 54

MRI 107  
 perfusion studies 113  
 myocardial scintigraphy 68, 70  
 stress-strain relationships, tissue Doppler imaging 46, 53-4  
 stroke volume, echocardiographic assessment 48  
 subclavian artery, aberrant right 264  
 subendocardial vs transmural infarction or scar 196, 197  
 surgery  
 pulmonary vascular tumors 259  
 ventricular aneurysm 199  
 Svensson classification of aortic dissection 271, 272-80  
 class 1 272-6  
 class 2 277  
 class 3 277  
 class 4 278-9  
 class 5 279-80  
 symptoms and signs of heart disease 3-4  
 synchrotron radiation, atherosclerosis 174, 177  
 syncope 4  
 syndrome X 200-1  
 syphilitic aortitis 280  
 systole  
 cardiac function in, echocardiographic assessment 52  
 pulmonary arterial pressure in, echocardiographic calculation 51



T1-weighted images 98  
 T2-weighted images 98  
 tachycardias 3-4  
 Takayasu arteritis 280  
 Tako Tsubo cardiomyopathy 227  
 tamponade, pericardial, in pericarditis 245-6, 246, 247  
 technetium-99m-labelled tracer (sestamibi) 69, 70  
 Tei index 52  
 teratoma 233, 238  
 tetrafosmin 70  
 thallium chloride 69  
 thermomodulation methods, cardiac output measurement 60-1  
 thermography, atherosclerotic plaque 176  
 thoracic aortic aneurysm 30  
 three-chamber views (MRI) 95  
 three-dimensional echocardiography 35-6  
 atrial volume, left 43  
 ventricular wall motion studies 53  
 three-dimensional MR angiography of great vessels 128, 130  
 thromboembolic pulmonary hypertension, chronic 255-6  
 CT angiography 86  
 MR angiography 133  
 thrombosis  
 intracardiac 240-1  
 ventricular 200  
 plaque 172, 173, 175  
 venous, leading to pulmonary embolism 252  
 tilting-disk valves 166, 168  
 time-delayed excitation 34  
 time-resolved contrast-enhanced MRA 130  
 tissue Doppler echocardiography 45  
 in chronic CAD 190, 195  
 mitral insufficiency 153  
 prosthetic valves 169  
 reference values 46-7  
 ventricular wall-motion studies 53-4  
 total anomalous pulmonary venous drainage 260-1

tracers  
 in FDG-PET 72-3  
 radioactive *see* radiotracers

tracking in RF data (strain rate imaging) 47

transesophageal echocardiography 39, 40-1

transfemoral approach to catheterization *see* femoral artery catheterization

transmural vs subendocardial infarction or scar 196, 197

transposition of great vessels 102

transseptal cardiac catheterization 59

transthoracic echocardiography 40

transvalvular flow velocity, Doppler studies 46, 47

traumatic aortic injury/rupture 279-80  
 CT angiography 87  
 radiography 30

tricuspid valve  
 combined disease of pulmonary and 165  
 insufficiency 163-4  
 MRI 96, 97  
 stenosis 162-3  
 systolic regurgitant jet across 50

tumors  
 cardiac 232-42, 250  
 benign 232  
 diagnostic techniques 233  
 malignant *see* malignant tumors  
 pulmonary vascular 133, 256-60, 261-2

turbo (fast) spin-echo (TSE/FSE) sequences 92, 98-100  
 morphological imaging 98, 98-100  
 single-shot *see* single-shot turbo spin-echo

two-chamber view (MRI) 95

two-dimensional echocardiography 35  
 LV function 52  
 quantification using 42-3

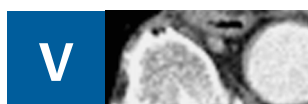


Uhl anomaly 226

ulcers (atheromatous plaque-associated)  
 aorta 278-9  
 coronary arteries 172

ultrasound  
 basic principles 35-6  
 cardiac *see* echocardiography  
 intravascular *see* intravascular ultrasound

ultrasound stethoscope 36



Valsalva's sinus, aneurysm 242

valves (cardiac) 141-69  
 acquired disease 141-69  
 vegetations 234

Doppler studies of flow velocity across 46

echocardiographic assessment  
 orifice area 49  
 regurgitant volume 48-9  
 MRI 96-7  
 insufficiency and stenosis 110  
 prosthetic 166-9  
*see also specific valves*

vascular anomalies, congenital *see* congenital cardiovascular anomalies

vasodilation induction in echocardiography 38

vasospastic angina pectoris 201

vegetations, valvular 234

venous congestion, pulmonary 12, 18, 21

venous grafts for coronary bypass 201, 203

venous thrombosis leading to pulmonary embolism 252

ventricles  
 aneurysms 198-200  
 angiography  
 LV 61  
 RV 61  
 arrhythmogenic RV dysplasia/cardiomyopathy *see* arrhythmogenic RV dysplasia/cardiomyopathy  
 enlargement/dilatations  
 LV 6-8, 11  
 radiographs 5-8  
 RV 5-6  
 function, echocardiographic assessment 51-6  
 LV 51-2  
 LV, in aortic dissection 275  
 RV 52-3  
 function, MRI assessment in chronic CAD 191  
 hypertrophy 11  
 inflow tract *see* inflow tract  
 isolated non-compaction of LV 227  
 motion *see* motion  
 MRI  
 of anomalies 102, 103  
 LV 94, 95  
 RV 96, 97  
 muscle mass, LV, echocardiographic estimation 41  
 nuclear imaging of LV 68, 72, 73  
 outflow tract *see* outflow tract  
 pressure, LV  
 echocardiographic studies of filling pressure 50, 55-6  
 echocardiographic studies of rise and fall 52  
 pressure, RV, echocardiographic studies 50, 51  
 pressure and/or volume overload  
 LV 11  
 RV 12  
 septal defect 144-6  
 echocardiographic studies 50-1, 145  
 thrombosis 200  
 volume *see* volume  
 wall *see* wall

vertical long axis (MRI)  
 LV 95  
 RV 96

viral infections, myocardial 228, 229

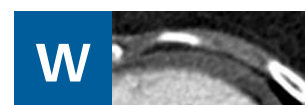
virtual histology, atherosclerotic plaque 175-6

visual analysis of perfusion MRI images 114-15

volume, chambers  
 echocardiographic estimation  
 LA 43, 43  
 LV 41, 43  
 RV 43  
 MRI, ventricles 104  
*see also* regurgitant volume; stroke volume

volume calcium score 77

volume overload 11  
 causes 12  
 heart failure due to 20  
 volume rendering technique 82  
 coronary bypass 202, 204



wall  
 aortic, increased tension causing dissection 272  
 cardiac/myocardial/ventricular motion *see* motion  
 thickness determination 195

water, <sup>15</sup>O-labelled, for PET 72


WHO classification of cardiomyopathies 22-3, 215

whole-heart MR coronary angiography 121

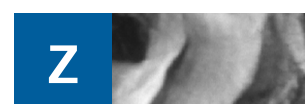Williams-Bueren syndrome 264

women with coronary heart disease, myocardial scintigraphy 71

World Health Organization of cardiomyopathies 22-3, 215



X-rays  
 in CT 80  
 for plain films *see* radiography



zero filling, MR angiography of great vessels 128-9