

# 1 A Three-Dimensional Approach to Facial Anatomy for the Injector

## Abstract

Facial anatomy for the injector is predicated upon a strong understanding of the three-dimensional architecture of the face. This chapter will describe the concentric layers of the face as well as the symphony of structures in the face that can be utilized by the injector to optimize outcomes.

**Keywords:** Superficial musculoaponeurotic system (SMAS), retaining ligaments, potential spaces, facial fat compartments

## 1.1 Facial Skeleton

Anatomy for the facial injector is unique and complex. It is paramount that the injector has a comprehensive understanding of the three-dimensional architecture of the face. The authors urge injectors to consider the superficial musculoaponeurotic system (SMAS) as a depth gauge to assist in navigating from superficial to deep and vice versa during clinical injection.

Simplistically, the face has five concentric layers (► Fig. 1.1, ► Fig. 1.2, ► Fig. 1.3, ► Fig. 1.4).

- **Layer 1** is the facial skeleton and periosteum.
  - Facial skeleton loses bone mineral density with age resulting in morphological changes.
- **Layer 2** is the “sub-SMAS” plane.
  - It contains deep fat compartments, potential spaces, and the origins of the “true” osseocutaneous retaining ligaments.
- **Layer 3** is the SMAS layer.
- **Layer 4** is the “supra-SMAS” layer.
  - It contains the superficial fat compartments and the retinacular cutis extension of the “true” osseocutaneous retaining ligaments.
- **Layer 5** is the skin.

## 1.2 The Birthday Cake Analogy (The Layers of the Face)

A relatable analogy is comparing the facial layers to a two-tiered birthday cake. The platter of the cake is the facial skeleton, which undergoes resorption and alteration during the aging process. The first layer of cake is the “sub-SMAS” layer

containing the deep facial fat compartments, potential spaces (i.e., upper temporal space aka interfascial plane, prezygomatic space, deep pyriform space), and the origins of the “true” osseocutaneous retaining ligaments (i.e., main zygomatic retaining ligament, orbital retaining ligament, zygomaticocutaneous retaining ligaments, mandibular osseocutaneous retaining ligament, platysma mandibular ligament). The middle layer of icing is the SMAS layer. In several locations in the face, the vasculature is commonly intertwined within the confines of SMAS layer and its analogues such as the superficial temporal fascia.

The top layer of cake is the “supra-SMAS” plane that contains the superficial fat compartments of the face, which are divided by vascular septae as well as the retinacular cutis of the facial retaining ligaments. One could consider the structure of the osseocutaneous retaining ligaments as a tree. In the deep layer of the face, the ligament is robust and compact like the trunk of a tree. As the ligament traverses superficial through the SMAS to eventually insert onto the skin the ligament “arborizes” into a branching pattern titled the retinacular cutis.

The top layer of icing is the skin which contains topographic anatomy reflecting the deeper layers of the face and their respective anatomical structures (i.e., lid-cheek junction, nasojugal groove, nasolabial fold, marionette crease) (► Fig. 1.5, ► Fig. 1.6, ► Fig. 1.7, ► Fig. 1.8).

## 1.3 The SMAS as a “Depth Gauge”

As the facial injector navigates the anatomy of the face, consideration should be given to the interplay and/or symphony of structures that contribute to each three-dimensional subunit in the face. For example, the injector can use the SMAS as a depth gauge to predictably access the deep layer of the face or as a stopping point to remain in the subcutaneous layer of the face. Then the injector can target specified fat compartments and/or potential spaces building between or within the facial retaining ligaments while exercising the appropriate amount of caution to avoid the vessels and lymphatics.

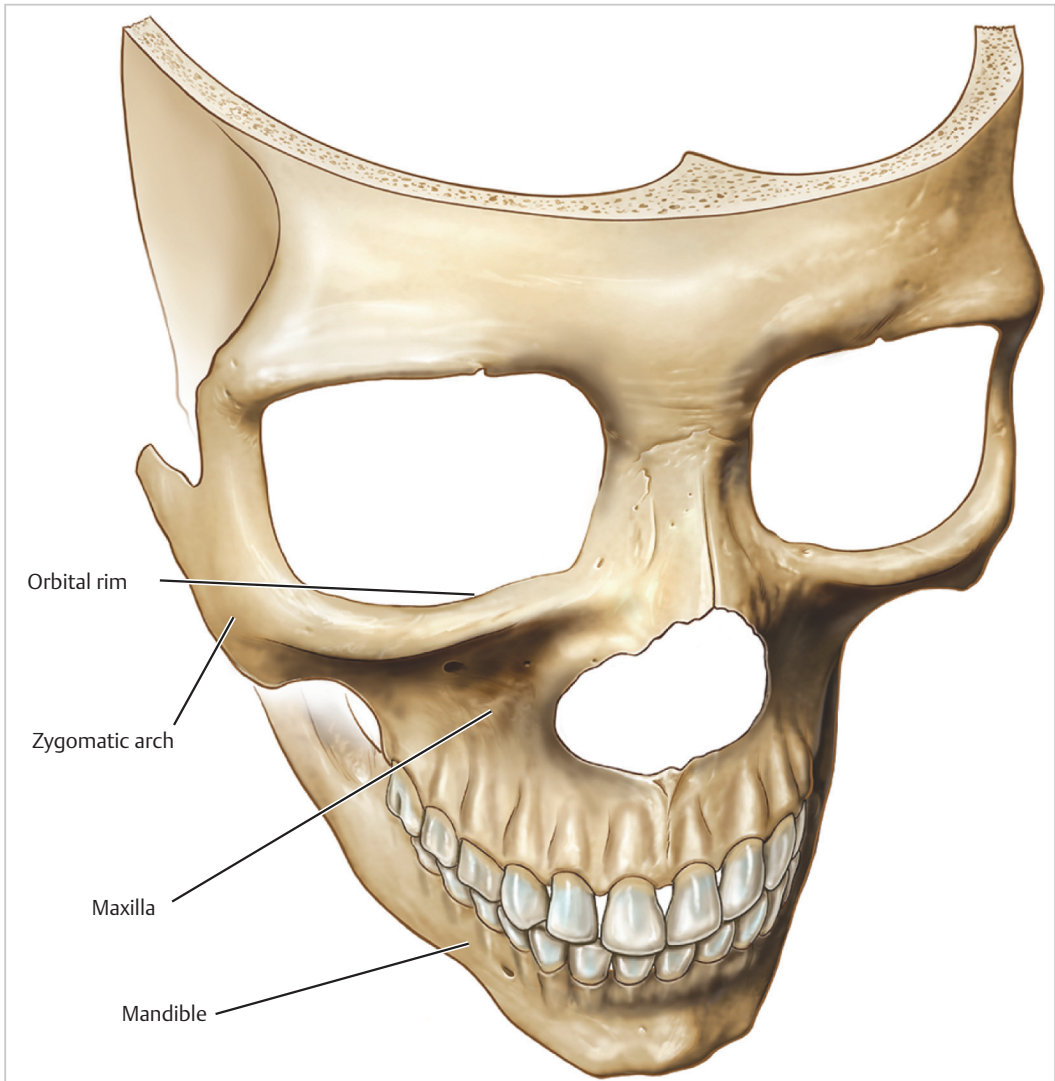
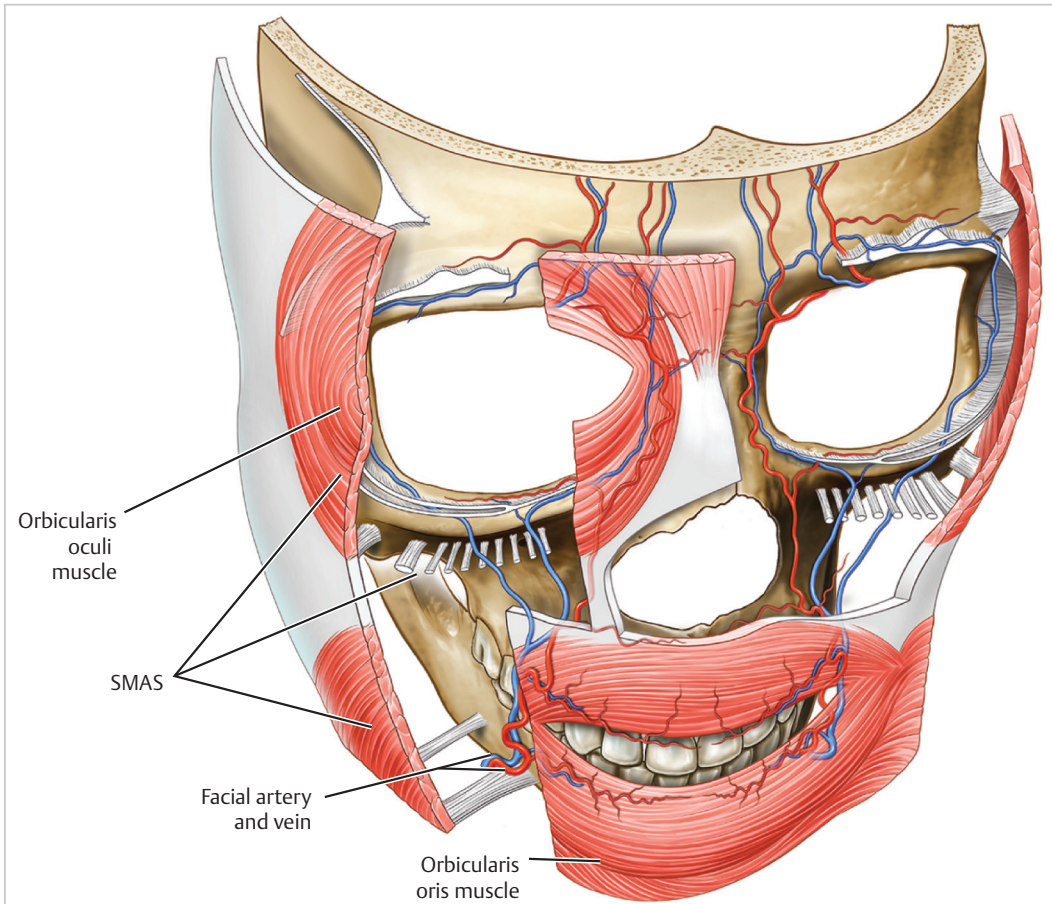
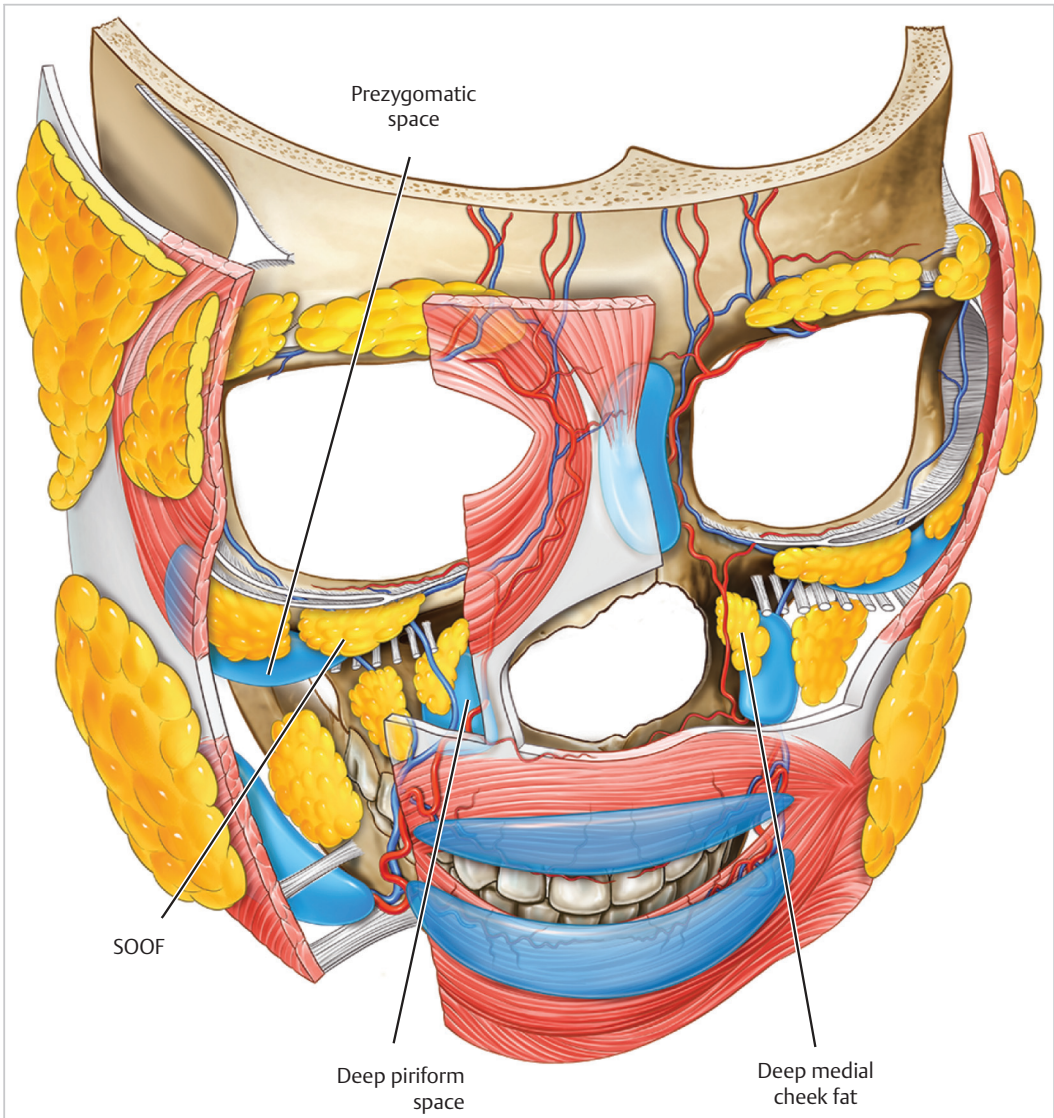


Fig. 1.1 Anatomic illustration of the facial skeleton. © Dr. Levent Efe, CMI.



**Fig. 1.2** Anatomic illustration of layer 4 of the face, also known as the “sub-SMAS plane” that contains the deep fat compartments of the face, the origin of the osseocutaneous retaining ligaments, and the gliding potential spaces of the face. SMAS, superficial musculoaponeurotic system. © Dr. Levent Efe, CMI.



**Fig. 1.3** Anatomic illustration of layer 3 of the face, also known as the “SMAS plane” that contains the muscles of facial animation as well as the arterial vasculature of the face in certain locations. SOOF, suborbicularis oculi fat. © Dr. Levent Efe, CMI.



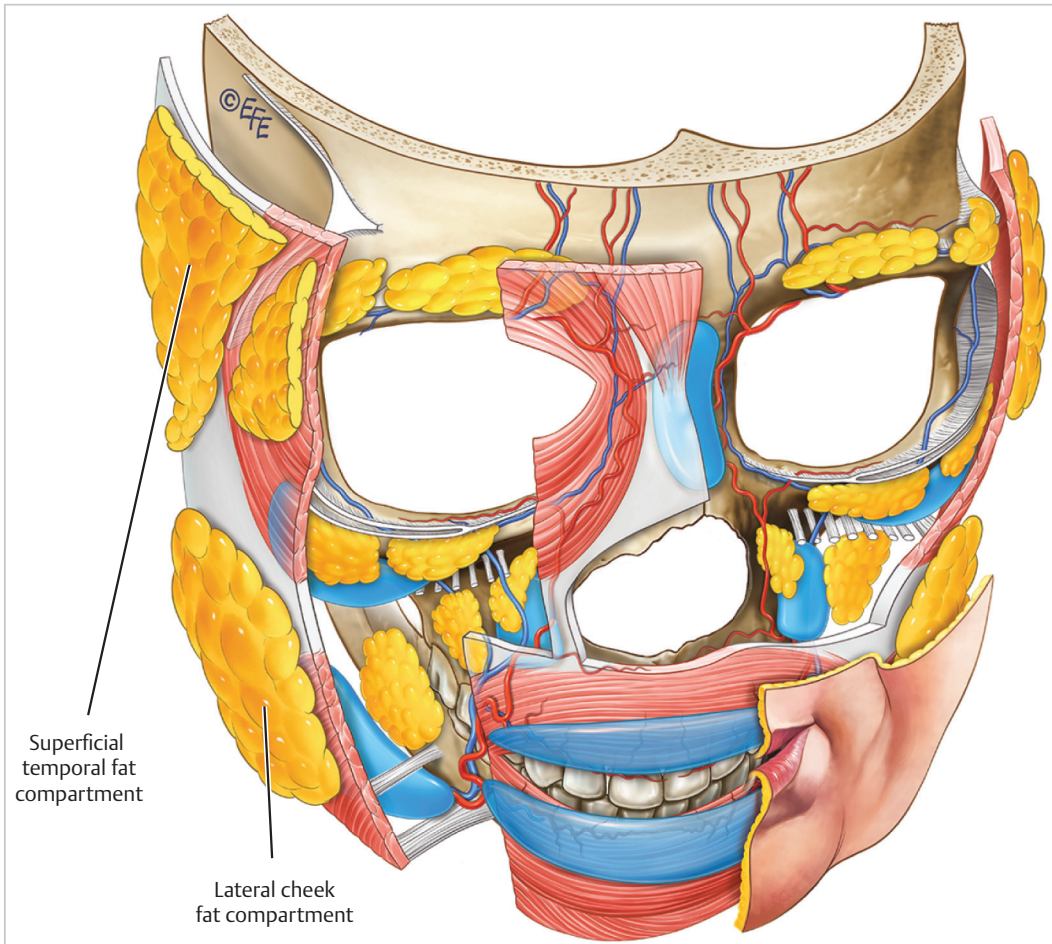
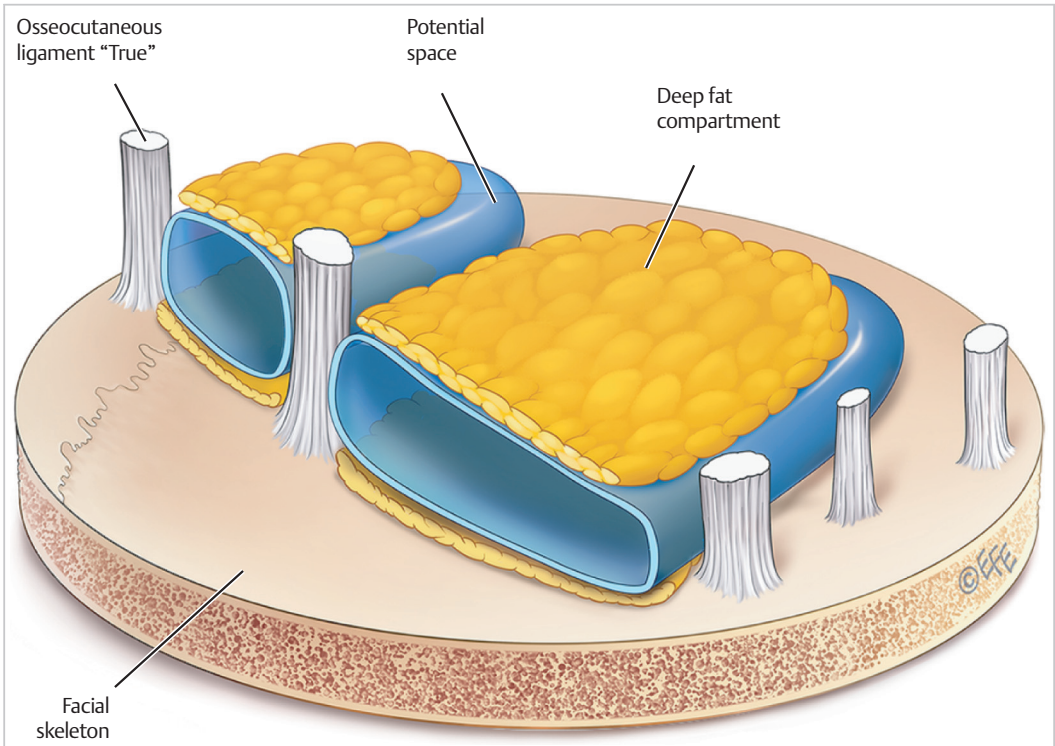
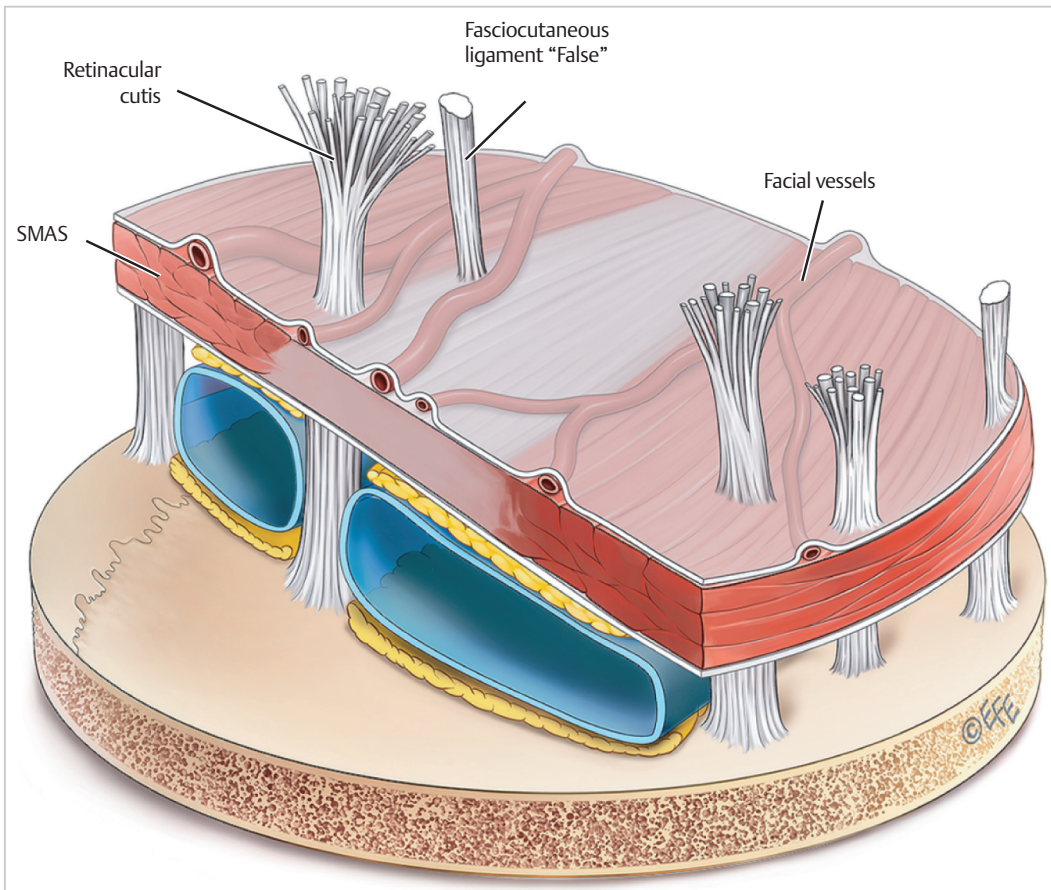


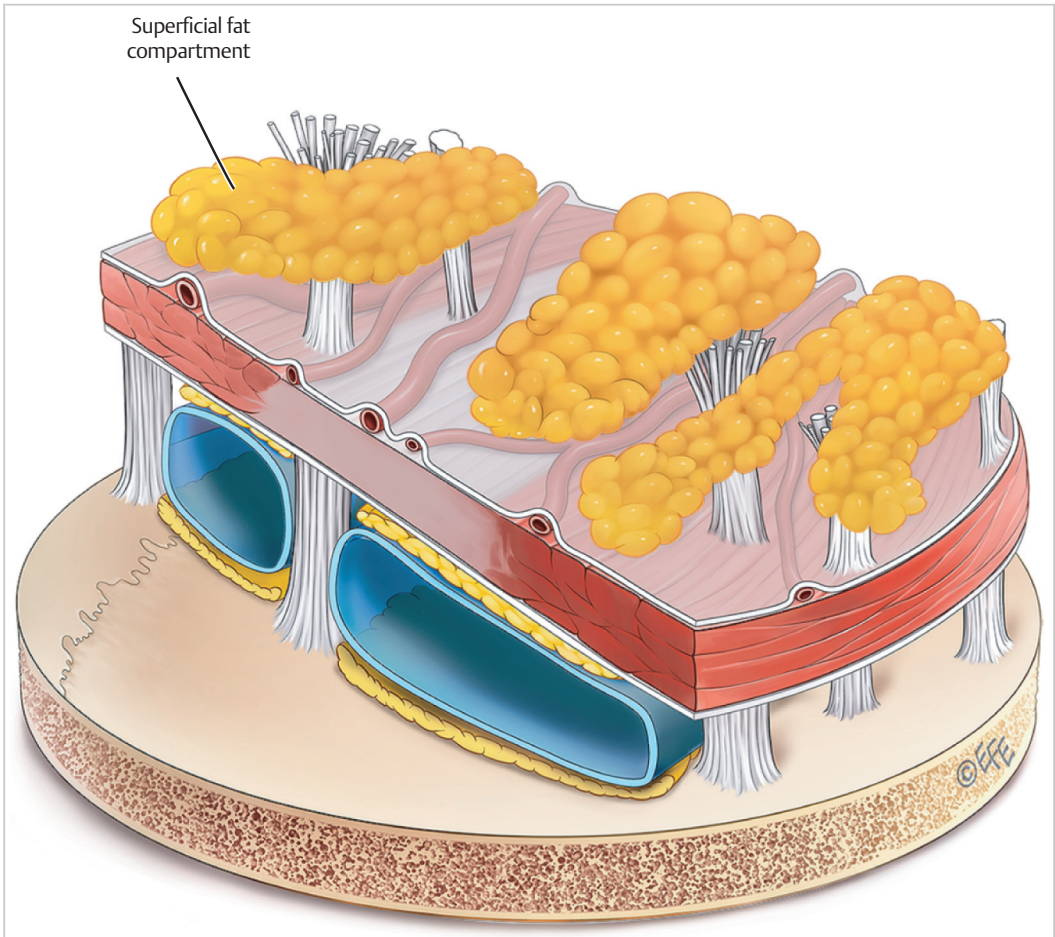
Fig. 1.4 Anatomic illustration of layer 2 of the face containing the superficial fat compartments and the branching retinacular cutis of the osseocutaneous retaining ligaments. © Dr. Levent Efe, CMI.



**Fig. 1.5** Anatomic illustration with “cake layer” analogy demonstrating layer 4 of the face, also known as the “sub-SMAS plane” that contains the deep fat compartments of the face, the origin of the osseocutaneous retaining ligaments, and the gliding potential spaces of the face. © Dr. Levent Efe, CMI.

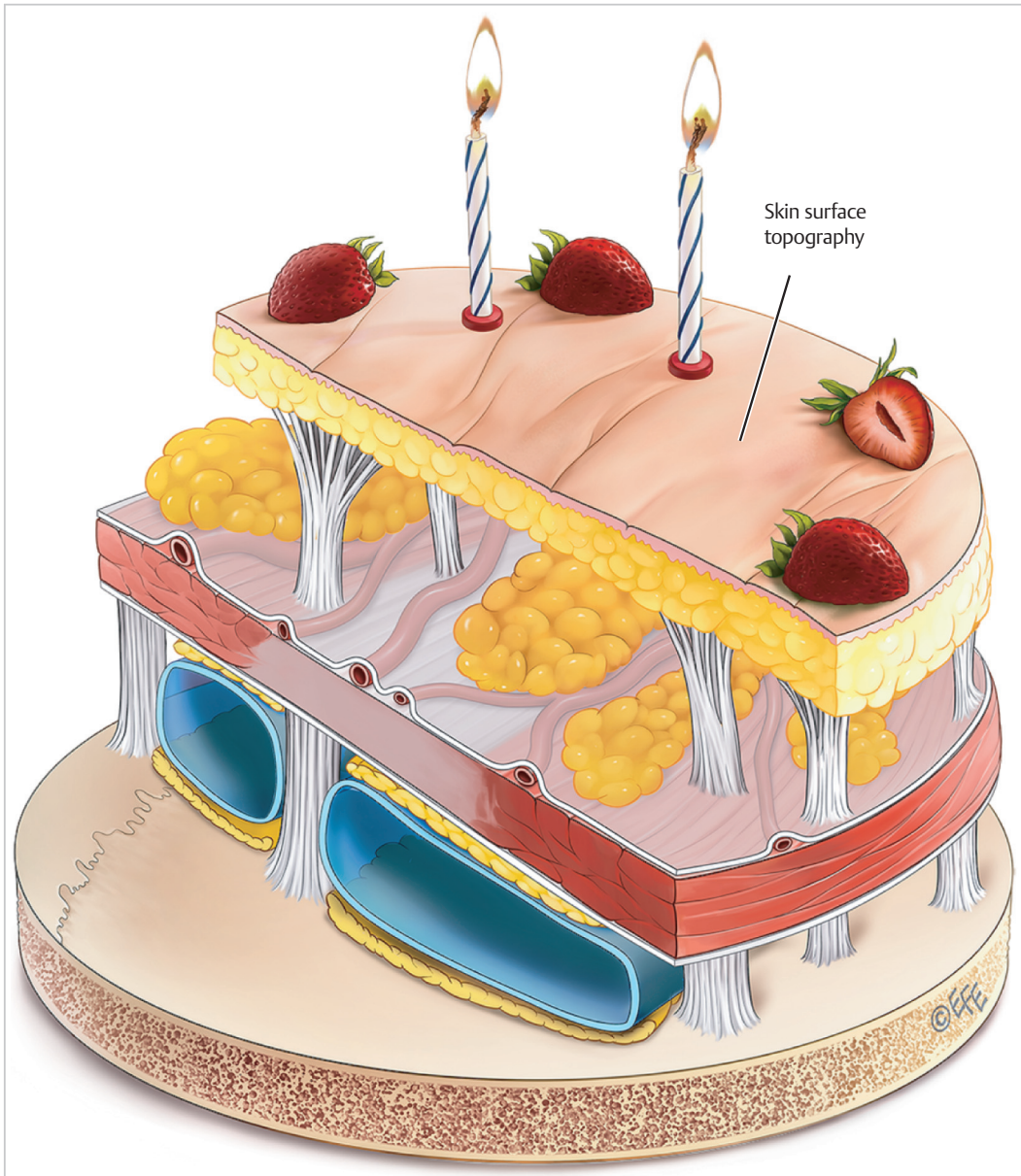


**Fig. 1.6** Anatomic illustration with “cake layer” analogy demonstrating layer 3 of the face, also known as the “SMAS plane” that contains the muscles of facial animation as well as the arterial vasculature of the face in certain locations. SMAS, superficial musculoaponeurotic system. © Dr. Levent Efe, CMI.



**Fig. 1.7** Anatomic illustration with “cake layer” analogy demonstrating layer 2 of the face containing the superficial fat compartments and the branching reticular cutis of the osseocutaneous retaining ligaments. © Dr. Levent Efe, CMI.





**Fig. 1.8** Anatomic illustration with “cake layer” analogy demonstrating layer 1 of the face, which contains the skin and the associated surface topography that results from cutaneous insertions of the osseocutaneous retaining ligaments (i.e., lid–cheek junction and nasojugal groove) as well as other shadowing and contour changes that result from aging anatomy and facial shape alterations. © Dr. Levent Efe, CMI.

These anatomical concepts can be applied to the various aesthetic subunits of the face and aid the injector as to navigate desired targets and avoid potential danger zones during clinical injection.

### Suggested Readings

Lamb J, Surek C. Facial Volumization: An Anatomic Approach. 1st ed. New York, NY: Thieme Medical Publishers; 2017

Mendelson B, Wong CH. Anatomy of the aging face. In: Neligan PC, ed. Plastic Surgery. Philadelphia, PA: Elsevier; 2013:78-92

Pessa J, Rohrich R. Facial Topography: Clinical Anatomy of the Face. St. Louis, MO: Quality Medical Publishing; 2012

Surek C. Facial Anatomy for Filler Injection: The Superficial Musculoaponeurotic System (SMAS) Is Not Just for Facelifting. *Clin Plast Surg.* 2019;46(4):603-612

Walker L, Cetto R. Facial Ageing and Injection Anatomy. 1st ed. UK Book Publishing; 2021