

Erratum

Kubale, Stiegler, Weskott (eds)

Vascular Ultrasound, 1st edition

ISBN 978-3-13-240543-1

Dear Readers,

We would like to inform you of the following corrections in chapter 5:

- Page 114: The legend for Fig. 5.38b should read, “Contralateral hyperplasia with a luminal diameter of 4.5mm.”
- Page 115: The legend for Fig. 5.41 should read, “Vertebral artery waveform produced by a proximal obstructive lesion.”
- Page 115: The legend for Fig. 5.42 should read, “Proximal occlusion of vertebral artery (white arrows) with collateral flow via cervical collaterals.”
- Page 115, right column: The sentence, “When Doppler spectral analysis shows...” should refer to Fig. 5.41.
- Page 117, left column: The sentence, “In a proximal occlusion of the basilar artery...” should refer to Fig. 5.40.

We apologize for these errors. Please also see the corrected pages below.

Georg Thieme Verlag



Extracranial Cerebral Arteries

with an anomalous course. Thus, for example, the hypoplastic vertebral artery may not communicate with the basilar artery and instead may be continuous with the posterior inferior cerebellar artery. Perhaps the only clinical significance of hypoplasia is that the affected vessel is not available to compensate for contralateral hypoperfusion. The relevance for vascular imaging lies in the need to differentiate a harmless anomaly from a potentially dangerous vascular disease. Therefore, hypoplasia should be evaluated with great care. The detection of slow flow in a small-caliber vessel requires very precise equipment settings.

Ultrasound Evaluation

The diagnosis of hypoplasia involves the assessment of an essentially normal finding. It may be diagnosed when the

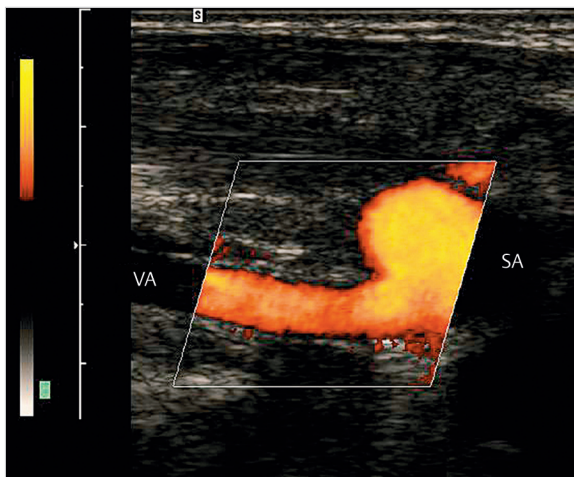


Fig. 5.37 Normal appearance of the vertebral artery in segment V0–V1. The vertebral artery (VA) is viewed in longitudinal section, the subclavian artery (SA) in transverse section.

luminal diameter is less than 2.5 mm, in which case the contralateral artery is usually hyperplastic. Very rarely, vertebral artery hypoplasia is bilateral and coexists with basilar artery hypoplasia. The flow velocity in the hypoplastic artery is low compared with the opposite side, and its pulsatility is usually increased (► Fig. 5.38). Differentiation is required from long-segment narrowing due to pathology such as dissection or vasculitis, and therefore the vessel wall should always be closely scrutinized in the B-mode image.

Anomalies of Origin and Course

In 5% of cases the left vertebral artery arises directly from the aortic arch. In this case stenosis of the subclavian artery cannot be collateralized via the vertebral artery (no subclavian steal). The vertebral artery does not enter the cervical spine at C6 in all cases (only about 90%); in 5% of cases the artery enters at C5, and in another 5% it enters the spine at a higher or lower level. When the vertebral artery enters at a high level, it often runs beside and parallel to the CCA for some distance. Anomalies of origin and course frequently coexist.

5.3.2 Stenosis

Stenoses and occlusions of the vertebral artery are often located at sites that cannot be directly visualized with ultrasound. Therefore, indirect signs of stenosis are particularly important. These criteria are basically the same for segmental occlusions and high-grade stenoses, with the result that stenoses and collateralized occlusions cannot always be distinguished.

Obstructive lesions of the vertebral artery are basically associated with the same hemodynamic changes as comparable lesions of the carotid artery. ► Fig. 5.40 and ► Fig. 5.41 show typical vertebral artery waveforms produced by distal or proximal obstructive lesions, each

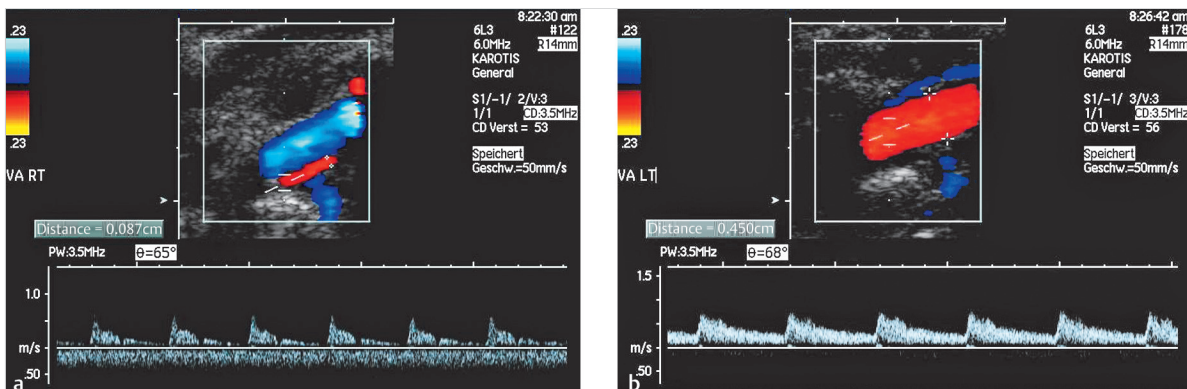


Fig. 5.38 Vertebral artery hypoplasia. (a) Narrow caliber with a luminal diameter less than 2 mm (measured in multiple segments). Spectral Doppler shows a reduced flow velocity and increased pulsatility. (b) Contralateral hyperplasia with a luminal diameter of 4.5 mm.

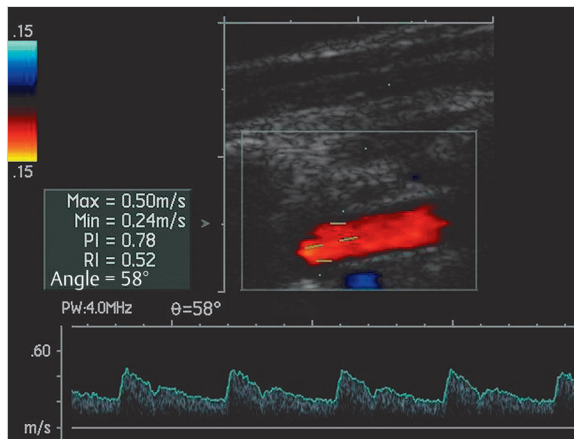


Fig. 5.39 Normal vertebral artery waveform.

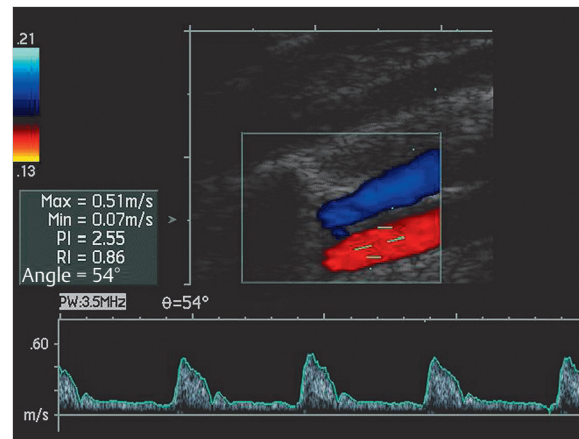


Fig. 5.40 Vertebral artery waveform produced by a distal obstructive lesion.

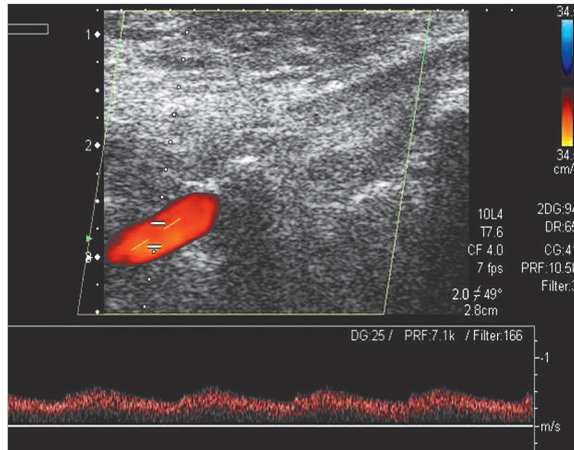


Fig. 5.41 Vertebral artery waveform produced by a proximal obstructive lesion.

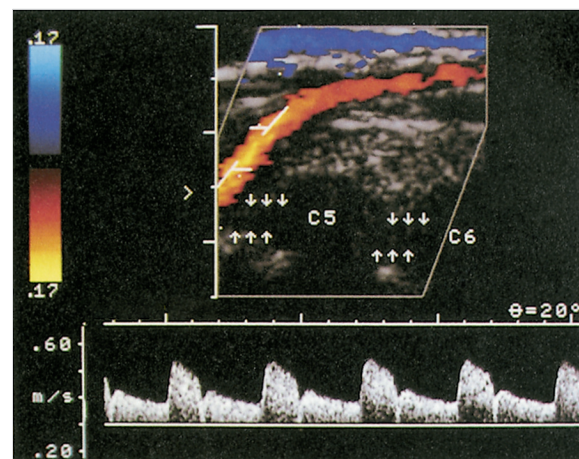


Fig. 5.42 Proximal occlusion of vertebral artery (white arrows) with collateral flow via cervical collaterals.

recorded in the V2 segment. The normal vertebral artery waveform is shown in ► Fig. 5.39 for comparison. Another criterion for proximal occlusion and high-grade stenosis is the detection of cervical collaterals (► Fig. 5.42).

Proximal Vertebral Artery Stenosis

Significance

Stenosis at the origin of the vertebral artery from the subclavian artery leads to cerebral ischemia only when a very high-grade stenosis is present. Sites of less severe stenosis rarely give rise to emboli, probably due to a different vessel-wall structure than in cases of carotid stenosis. Thus, the detection of moderate or low-grade, nonhemodynamically significant stenosis in the proximal vertebral artery does not have significant clinical implications.

Ultrasound Evaluation

In most cases the right vertebral artery, and often the left artery as well, can be traced down from the V2 segment to its origin. When Doppler spectral analysis shows a proximal-obstruction type of waveform in the V2 segment (► Fig. 5.41), an attempt should always be made to image the proximal vertebral artery in the color Doppler and spectral Doppler modes, even under difficult scanning conditions. The supplemental use of a sector or curved-array transducer (abdominal probe) may be helpful.

► Fig. 5.43 illustrates the typical findings associated with a stenosis at the origin of the vertebral artery. Criteria are not available for quantifying the stenosis, but whenever indirect signs of stenosis are noted like those in ► Fig. 5.40 and ► Fig. 5.42, it is reasonable to assume that a high degree of stenosis is present. A proximal

Ultrasound Evaluation

The goal of ultrasound is to differentiate among an occlusion, a stenosis, and a normal variant (hypoplasia). The sonographic diagnosis of occlusion is established when the findings meet all of the criteria listed below (► Fig. 5.44). In all cases, instrument settings should be optimized for the examination, including use of the correct transducer with the lowest possible operating frequency.

Diagnostic criteria for extracranial vertebral artery occlusion

The diagnosis is established when all four of the following criteria are met:

- The vertebral artery can be visualized in B-mode (excludes aplasia).
- There is no evidence of vertebral artery perfusion in color Doppler mode.
- There is no evidence of vertebral artery perfusion in spectral Doppler mode.
- The vertebral vein can be visualized in color Doppler mode (excludes poor scanning conditions).

Segmental occlusions in proximal or distal vascular segments not accessible to direct insonation can be diagnosed from indirect hemodynamic criteria (► Fig. 5.39, ► Fig. 5.40, ► Fig. 5.42). In a proximal occlusion of the basilar artery, the waveform changes shown in ► Fig. 5.40 are detectable in both vertebral arteries. In this case it is important to compare with findings in the (common) carotid artery to ensure that generalized waveform changes due to loss of compliance (advanced age, dilatative arteriopathy, or poor cardiac compliance) are not misinterpreted as stenosis. Occlusions in the terminal segment of the vertebral artery are not accessible to extracranial insonation.

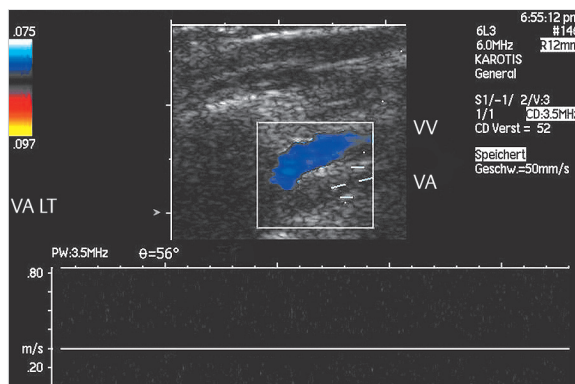


Fig. 5.44 Occlusion of the V2 segment of the vertebral artery.

5.3.5 Subclavian Steal

Definition

The term “subclavian steal” describes flow changes in the vertebral artery resulting from stenosis or occlusion of the subclavian artery.

Location

The obstructive lesion in the subclavian artery (or brachiocephalic trunk) must be located proximal to the origin of the vertebral artery. In 5% of cases, the left vertebral artery arises directly from the aortic arch.

Etiology

Proximal stenosis of the subclavian artery or brachiocephalic trunk may be due to atherosclerotic disease, vasculitis, radiation-induced angiopathy, or aortic dissection. There is a higher proportion of nonatherosclerotic lesions than in the carotid artery. Vasculitis is more commonly associated with long-segment stenosis or occlusion. Mechanical compression of the subclavian artery in the interscalene triangle or costoclavicular space always occurs distal to the origin and cannot cause subclavian steal.

Severity and Clinical Features

The severity of the steal effect in the vertebral artery depends on the following factors:

- Degree of subclavian artery stenosis
- Extracranial and intracranial collateralization

A continuum exists from a mildly altered spectral waveform with slight systolic deceleration to continuous retrograde flow with the vertebral artery functioning as a collateral channel (► Fig. 5.45). The condition is termed **subclavian steal syndrome** when it leads to provokable vertigo or other ischemic cerebral symptoms. Subclavian steal is asymptomatic in most cases, however, and it may remain asymptomatic even when retrograde flow is detectable in the basilar artery.

Ultrasound Evaluation

► Table 5.5 shows the findings in the subclavian artery or vertebral artery that are associated with a complete or incomplete subclavian steal. Although an upper arm compression test is routinely employed to detect continuous vertebral artery flow reversal in a simple Doppler examination, only equivocal cases will require a compression test in CDS.

In the treatment of subclavian steal syndrome, it is important to distinguish between subclavian artery stenosis, which is treatable by catheter dilatation, and an