

7.11 Radiation Retinopathy

Lothar Krause

Epidemiology, Pathophysiology, and Clinical Presentation

- Radiation retinopathy is a retinal vessel disease caused by the damaging effects of protons, beta rays, or gamma rays on the structure of vessel walls.
- This type of retinopathy can develop after external beam radiotherapy, after brachytherapy with ruthenium or iodine plaques, or after proton beam radiation. The severity depends on the dosage (starting at about 30 Gy), the size of the irradiated surface, and the type of fractionation used. Radiation retinopathy is observed more frequently in diabetic patients.
- Radiation retinopathy typically appears several months or years after the radiotherapy, due to chronic vessel wall damage. Clinically, occlusive vasculopathy becomes visible in the form of capillary occlusions and ischemic areas with microaneurysms, retinal hemorrhage, retinal edema, macular edema, and exudates. Neovascularizations may also develop (on the optic disc, retina, or iris).
- Radiation retinopathy is not limited to the areas that receive the maximum radiation energy, but can also be detected in vessels lying outside of the center of the radiation field.
- When the optic nerve head is involved, swelling of the optic nerve head and parapapillary hemorrhage (radiation neuropathy) may be observed, with progression to atrophy of the optic nerve.

Fluorescein Angiography

- The clinical picture is characteristic and is usually sufficient for diagnosis in patients with a history of radiation exposure. Fluorescein angiography makes it possible to identify avascular areas and also facilitates laser photocoagulation.
- Areas of hyperfluorescence appear on the optic nerve head in the early phase, as a result of leakage. Hypo-

fluorescence can be seen as a result of capillary occlusions and hemorrhage or retinal edema (or exudates).

- The arteriovenous phase shows areas of hyperfluorescence along the vessels, resulting from increased permeability of the damaged vessel walls, and dot-shaped areas of hyperfluorescence caused by microaneurysms and telangiectases.
- There is an increase in the areas of hyperfluorescence in the late phase, and cystoid macular edema can also be found in some cases.

Diagnosis and Treatment

- The case history and the clinical picture determine the diagnosis. Fluorescein angiography can confirm the location of the ischemic areas, capillary occlusions, microaneurysms, proliferations, and macular edema.
- The treatment depends on the degree and location of the vessel damage. As in other occlusive retinal diseases, panretinal laser coagulation is used to prevent or treat neovascularization. The prognosis for the preservation of visual acuity is very limited with radiation neuropathy, although cases of spontaneous resolution have been reported.

References

- Brown GC, Shields JA, Sanborn G, Augsburger JJ, Savino PJ, Schatz NJ. Radiation retinopathy. *Ophthalmology* 1982;89:1494–501.
- Gunduz K, Shields CL, Shields JA, Cater J, Freire JE, Brady LW. Radiation retinopathy following plaque radiotherapy for posterior uveal melanoma. *Arch Ophthalmol* 1999;117:609–14.
- Spaide RF, Leys A, Herrmann-Delemazure B, et al. Radiation-associated choroidal neovascularopathy. *Ophthalmology* 1999;106:2254–60.
- Takahashi K, Kishi S, Muraoka K, Tanaka T, Shimizu K. Radiation choroidopathy with remodeling of the choroidal venous system. *Am J Ophthalmol* 1998;125:367–73.

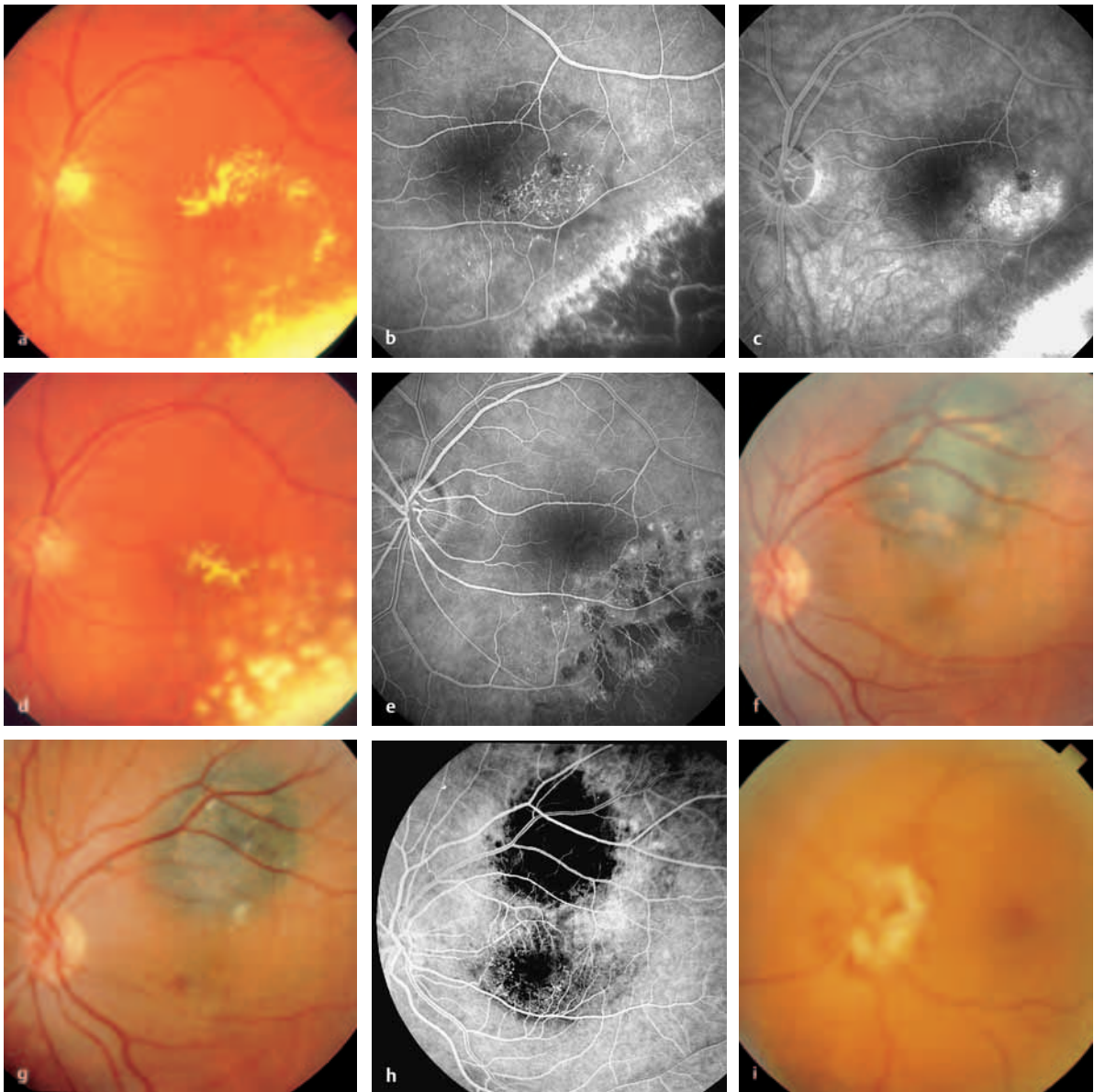


Fig. 7.11a–i **Radiation retinopathy**

- a** Color photograph. The edge of a radiation scar after ruthenium plaque radiotherapy for a choroidal melanoma can be seen in the lower part of the image. Beyond the radiation scar, microaneurysms, dot hemorrhages, hard exudates, and macular edema are all visible at the posterior pole.
- b** Arteriovenous phase. Central to the scar, an area with telangiectatic neovascularization, small, dot-like extravascular areas of hyperfluorescence in the microaneurysms, and leakage are visible as signs of vessel wall damage. The clinically visible hard exudates are no longer identifiable. The choroidal vessels are visible in the radiation scar as a result of damage to the retinal pigment epithelium and choriocapillaris.
- c** Late phase. There is increasing leakage in the area described above, up to and into the fovea, with reduced visual acuity. Hyperfluorescence is also visible in the area of the radiation scar.
- d** Color photograph. The same patient, with regression of the central exudates visible 6 months after laser coagulation of the affected area.

- e** Arteriovenous phase. Markedly fewer telangiectatic vessels are visible. The choroidal vessels are recognizable in the areas of laser treatment and radiation scarring.
- f** Color photograph. A choroidal melanoma with orange pigment in the upper temporal vessel arcade.
- g** Color photograph. Cotton-wool spots and hemorrhages indicating vessel damage and radiation retinopathy at the posterior pole are recognizable after proton therapy.
- h** Arteriovenous phase. There are areas of hypofluorescence due to blockage in the tumor area. Telangiectatic vessel alterations in the parafoveal capillary network are recognizable outside of the actual radiation field in the macula. These subsequently lead to further leakage and thus to macular edema.
- i** Color photograph. Radiation neuropathy in a different patient after proton-beam therapy for a large choroidal melanoma in the nasal area (tumor not shown).