

- b. When the patient turns their head, the common carotid artery and the jugular vein move medially out of the path of the needle, and when the fingers are pressed in, artery and vein are in any case both pushed completely out of the way (Fig. 3.66). Generally, the carotid tubercle (the well-developed anterior tubercle of the transverse process of the sixth cervical vertebra) can then be clearly felt further in, so that one does not have to penetrate into the unknown! The techniques of Herget and Leriche are directed more caudally for the head of the first rib in front of the body of the seventh cervical vertebra. My technique aims one vertebral level cranially for the transverse process of the sixth cervical vertebra. This provides greater safety through distance to the pleura, avoiding the risk to cause pneumothorax, which was a relatively frequent complication with the direction of the head of the first rib (Herget). Anatomical research has shown that the stellate ganglion is closely connected with the top of the pleura and even covered up to 70% by pleura (Hahn-Godeffroy, Jelisarowski). The only vital risk we can see is that of an accidental intradural injection, but this can be avoided not only by aspiration (hence never work with too thin a needle!) but also by

observing the most important safety rule of all: when injecting, always maintain loose contact with the transverse process of the sixth cervical vertebra and take care not to slide further dorsally with the point of the needle. Neither of these is difficult to check and will prevent complications.

- c. In asthmatics and patients with emphysema, there is no risk of perforating the distended apex of the lung, since this is also pushed down and out of the way with the fingers.
- d. No special needle is required and it is even possible to administer this injection during a domiciliary visit to a bed-ridden patient.
- e. Provided a few simple precautions are observed, complications are practically impossible, and it is true to say that this injection is no more risky than an intravenous one. It has proved its worth in my own personal experience in over 50 000 injections, with not a single mishap. Because of its enormous action radius, every practitioner should be thoroughly familiar with it and use it daily, wherever it is necessary and indicated.

Werthmann, a pediatrician from Salzburg, showed that my technique is successfully used with infants and toddlers. Parents and children usually reject lengthy segmental therapy, thus, the pediatrician

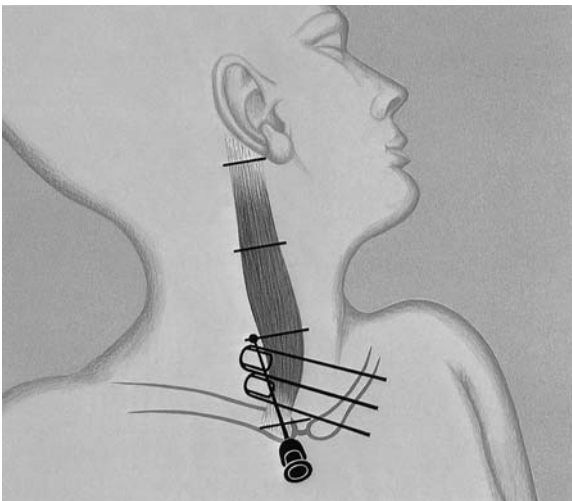


Fig. 3.66 Diagram showing the injection site for the injection to the stellate ganglion according to Leriche's method as modified by Dosch. The head of the seated patient is turned in the opposite direction to that of the injection and bent back. Two or three fingers of the left hand press in above the sternum on the outer edge of the sternocleidomastoid. The head of the first rib now lies almost subcutaneously above the topmost finger. In boxing, a blow to this area can produce a carotid-sinus reflex and may result in a knockout.

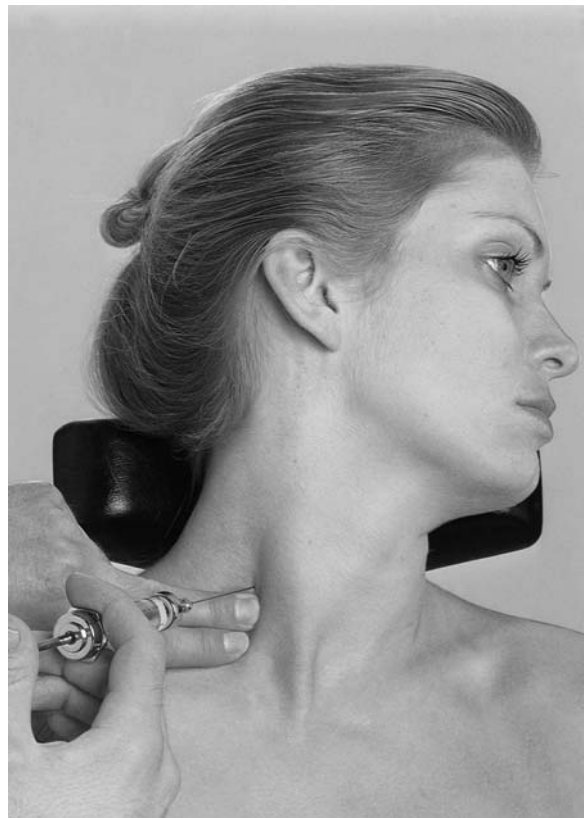


Fig. 3.67 Injection to the stellate ganglion according to Dosch.