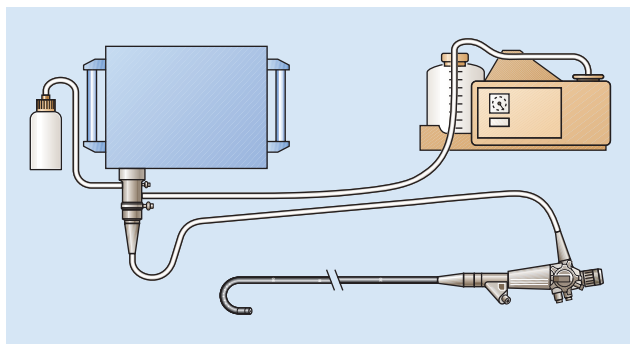
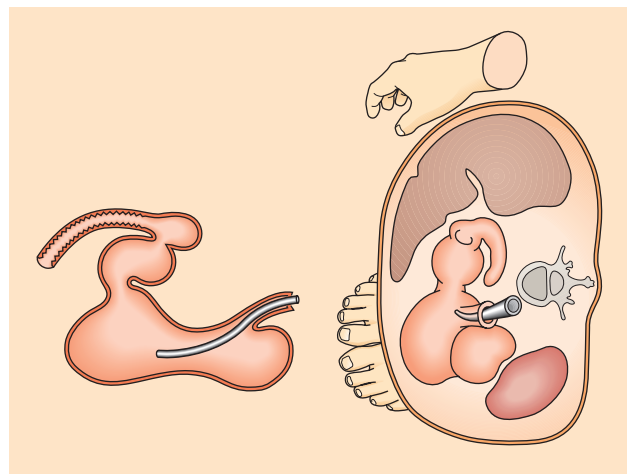


Contents



1 General ... 1

Indications and Contraindications ...	2
Risks and Complications: Cardiac and Pulmonary ...	3
Local Anesthesia ...	3
Sedation and Analgesia ...	3
Cardiac Complications ...	3
Respiratory Complications ...	3
Risks and Complications: Gastrointestinal ...	4
Perforation and Bleeding ...	4
Infection ...	4
Endoscopy Suite: Facilities and Staff ...	5
Procedure Room ...	5
Staff ...	5
Endoscopy Unit ...	5
Endoscopy Suite: Endoscope ...	6
Endoscopy Suite: Accessories ...	7
Endoscopic Accessories ...	7
Emergency Equipment ...	7
Documentation of Findings ...	7
Preparations for Endoscopy: Informed Consent ...	8
Disclosure and Informed Consent ...	8
Preparations for Endoscopy: Medications (1) ...	9
Premedication and Medications Used During the Procedure ...	9
Preparations for Endoscopy: Medications (2) ...	10
Checklists Before, During, and After the Examination ...	11
Diagnosis and Treatment of Complications (1) ...	12
Complications During the Examination ...	12
Diagnosis and Treatment of Complications (2) ...	13
Diagnosis and Treatment of Complications (3) ...	14
Complications Immediately After the Examination or After a Complaint-Free Interval ...	14
Diagnosis and Treatment of Complications (4) ...	15
Diagnosis and Treatment of Complications (5) ...	16
Endoscopic Technique: Steps in Learning ...	17
Learning the Examination Technique ...	17
Handling the Endoscope ...	17
Endoscopic Technique: Maneuvering the Scope ...	18
Endoscopic Technique: Functions ...	19



2 Examination Technique and Normal Findings ... 20

Inserting the Endoscope ...	22
Basic Rules ...	22
Blind Insertion ...	23
With Visual Control ...	23
Passage through the Upper Esophageal Sphincter ...	23
Direct-Vision Insertion ...	24
Problems ...	24
Direct-Vision Insertion: Four Phases ...	25
Upper Esophageal Sphincter ...	26
Anatomy ...	26
Physiology ...	26
Cervical Esophagus ...	27
Anatomy ...	27
Middle Esophageal Constriction ...	28
Anatomy ...	28
Inspecting the Middle Esophageal Constriction ...	29
Retrocardiac Esophagus ...	30
Anatomy ...	30
Distal Esophagus and Lower Esophageal Constriction ...	31
Anatomy ...	31
Gastroesophageal Junction ...	32
Anatomy ...	32
Physiology ...	32
Closure Mechanisms ...	32
Lower Esophageal Sphincter and Diaphragmatic Hiatus ...	33
Anatomy ...	33
Z-Line ...	34
Anatomy ...	34
Swallowing and Esophageal Motility ...	35
Physiology ...	35
Terminology of Esophageal Motility ...	35
Examining the Stomach During Insertion ...	36
Technical Aspects ...	36
Advancing the Endoscope ...	36

Views: Fundus–Body Junction and Gastric Body ... **37**

Views: Body–Antrum Junction and Antrum ... **38**

Views: Pylorus ... **39**

Gastric Body ... **40**
 Details ... 40

Body–Antrum Junction and Antrum ... **41**
 Details ... 41

Antral Region ... **42**

Antral Peristalsis ... **43**

Retroflexion Maneuver ... **44**
 Components of Retroflexion ... 44

Retroflexion in the Stomach ... **45**
 Maneuvering the Endoscope ... 45

Inspection of the Fundus ... **46**
 Maneuvering the Endoscope ... 46

Inspection of the Cardia ... **47**
 Maneuvering the Endoscope ... 47

Relations of the Stomach: Abdominal Wall ... **48**
 Anatomy ... 48
 Identifying the Abdominal Wall ... 48

Relations of the Stomach: Pancreas ... **49**
 Impression from the Pancreas ... 49

Relations of the Stomach: Liver ... **50**
 Impression from the Inferior Hepatic Border ... 50

Relations of the Stomach: Heart and Spleen ... **51**
 Cardiac Notch, Impressions from the Heart
 and Spleen ... 51

Passage into the Duodenal Bulb ... **52**
 Passing the Endoscope ... 52

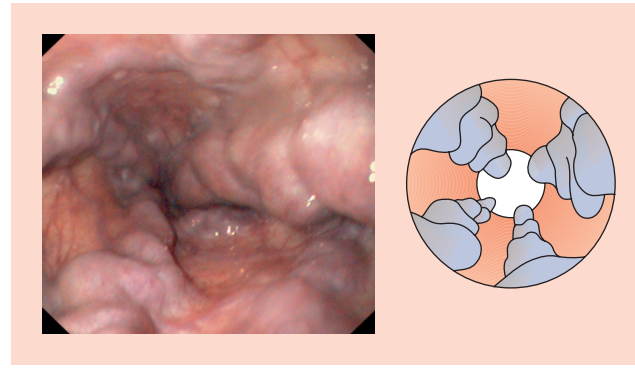
Passage into the Descending Duodenum ... **53**
 Maneuvering the Endoscope ... 53

Views: Bulbar and Proximal Duodenum ... **54**

Views: Descending Duodenum and Superior
 Duodenal Angle ... **55**

Duodenal Bulb ... **56**
 Details ... 56

Descending Duodenum ... **57**
 Details ... 57



3.1 Pathological Findings: Esophagus ... **58**



Overview of Pathological Findings
 in the Esophagus ... **60**

Cardial Incompetence ... **61**
 Definition and Clinical Aspects ... 61
 Diagnosis ... 61

Hiatal Hernia: Axial Sliding Hernia ... **62**
 Definitions and Clinical Aspects ... 62
 Diagnosis ... 62

Hiatal Hernia: Paraesophageal Hernia ... **63**
 Definition ... 63
 Diagnosis ... 63

Hiatal Hernia: Upside-Down Stomach ... **64**
 Definition ... 64
 Diagnosis ... 64

Gastroesophageal Prolapse ... **65**
 Definition and Clinical Aspects ... 65
 Diagnosis ... 65

Mallory–Weiss Lesion and Boerhaave Syndrome ... **66**
 Definitions and Clinical Aspects ... 66
 Diagnosis ... 66

Gastroesophageal Reflux and Reflux Esophagitis:
 Clinical Aspects ... **67**
 Gastroesophageal Reflux ... 67
 Reflux Esophagitis ... 67

Reflux Esophagitis: Diagnosis and Treatment ... **68**
 Diagnosis ... 68
 Treatment ... 68

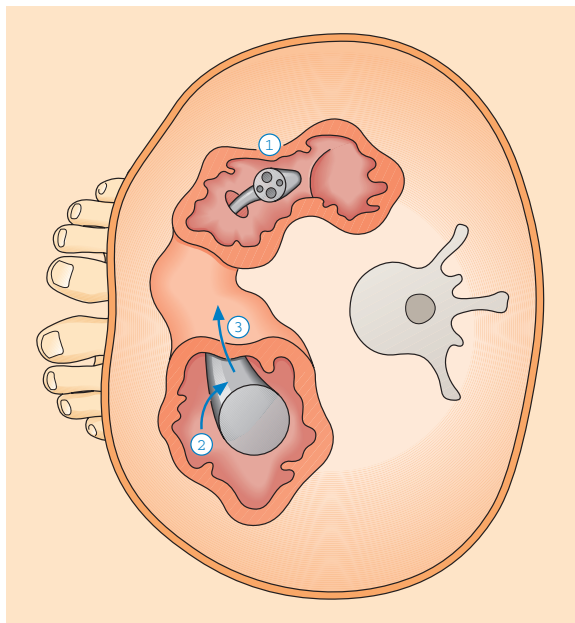
Reflux Esophagitis: Grading ... **69**
 Grade I–IV Reflux Esophagitis ... 69

Complications of Reflux Esophagitis:
 Barrett Esophagus ... **70**
 Definition and Clinical Aspects ... 70
 Diagnosis ... 70

Complications of Reflux Esophagitis: Management
 of Barrett Esophagus ... **71**
 Diagnosis ... 71
 Treatment and Follow-Up ... 71

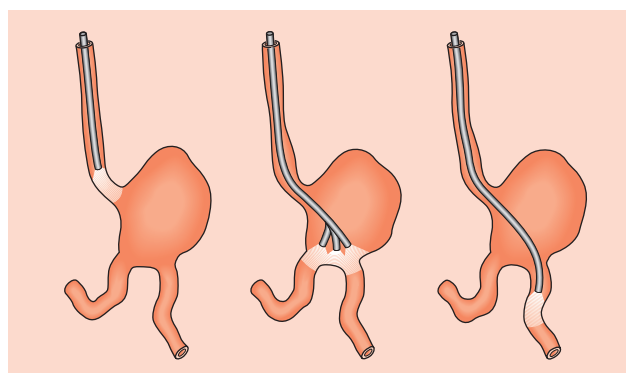
Complications of Reflux Esophagitis:
 Peptic Stricture ... **72**
 Pathophysiology ... 72
 Diagnosis ... 72

Candida Esophagitis ... **73**
 Pathophysiology ... 73
 Clinical Aspects ... 73
 Diagnosis ... 73



Viral Esophagitis: Herpes simplex and Cytomegalovirus ...	74
Pathophysiology ...	74
Clinical Aspects ...	74
Diagnosis ...	74
Treatment ...	74
Esophagitis due to Medications, Alcohol, or Foreign Bodies ...	75
Pathophysiology ...	75
Diagnosis ...	75
Alkaline Reflux Esophagitis and Radiogenic Esophagitis ...	76
Alkaline Reflux Esophagitis ...	76
Diagnosis ...	76
Radiogenic Esophagitis ...	76
Diagnosis ...	76
Esophagitis due to Corrosive Ingestion or Crohn Disease ...	77
Corrosive Ingestion ...	77
Diagnosis ...	77
Crohn Disease of the Esophagus ...	77
Synopsis of Inflammatory Lesions of the Esophagus ...	78
Clinical Complaints ...	78
Causes of Complaints ...	78
Differential Diagnosis ...	78
Diverticula: Definitions and Diagnosis ...	79
Definitions ...	79
Diagnosis ...	79
Diverticula: Details ...	80
Cervical Diverticulum ...	80
Thoracic Diverticulum ...	80
Epiphrenic Diverticulum ...	80
Achalasia: Clinical Aspects and Diagnosis ...	81
Clinical Aspects ...	81
Diagnosis ...	81
Achalasia: Treatment ...	82
Treatment Options ...	82
Follow-Ups ...	82
Diffuse Esophageal Spasm ...	83
Clinical Aspects ...	83
Diagnosis ...	83
Treatment ...	83
Nutcracker Esophagus and Motility Disorders in Scleroderma ...	84
Nutcracker Esophagus ...	84
Diagnosis ...	84
Esophageal Motility Disorders in Systemic Diseases: Scleroderma ...	84
Diagnosis ...	84
Normal Variants ...	84
Esophageal Varices ...	85
Anatomy ...	85
Clinical Aspects ...	85
Diagnosis ...	85
Esophageal Varices: Grading ...	86
Esophageal Varices: Signs of High Bleeding Risk ...	87
Assessing the Risk of Bleeding ...	87
Esophageal Varices: Treatment ...	88
Therapy ...	88

Esophageal Tumors: Overview of Benign Esophageal Tumors ...	89
Complaints ...	89
Differentiation of Benign Esophageal Tumors ...	89
Management ...	89
Benign Esophageal Tumors: Diagnosis ...	90
Malignant Esophageal Tumors: Diagnosis ...	91
Squamous Cell Carcinoma ...	91
Adenocarcinoma ...	91
Malignant Esophageal Tumors: Treatment and Follow-Up ...	92
Treatment ...	92
Follow-Ups ...	92
Postoperative Conditions ...	93
Type of Operation ...	93

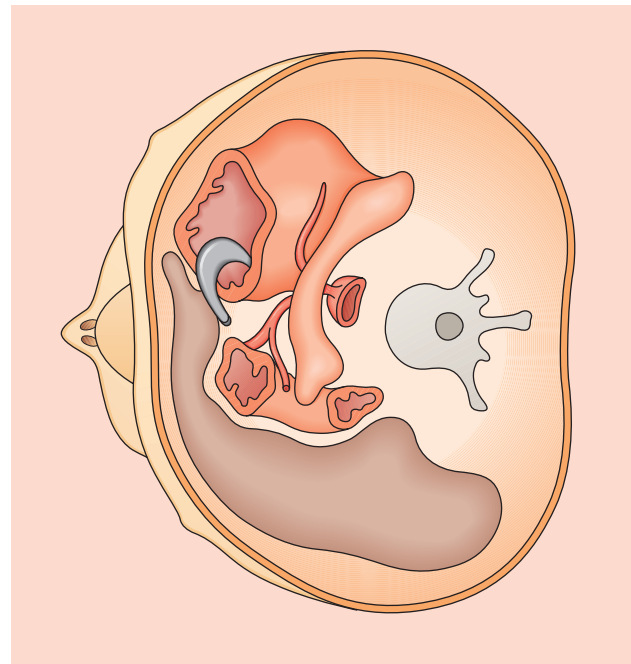


3.2 Pathological Findings: Stomach ... 94



Overview of Pathological Findings in the Stomach ...	96
Gastritis: Clinical Aspects ...	97
Acute Gastritis ...	97
Acute Gastritis: Diagnosis ...	98
Acute Gastritis: Differential Diagnosis and Treatment ...	99
Treatment ...	99
Chronic Gastritis: Clinical Aspects and Classification ...	100
Clinical Features ...	100
Classifications ...	100
Chronic Gastritis: Diagnosis, Giant Fold Gastritis, and Ménétrier Disease ...	101
Diagnosis of Chronic Gastritis ...	101
Giant Fold Gastritis ...	101
Ménétrier Disease ...	101
Gastric Ulcer: Clinical Aspects and Diagnosis ...	102
Definition and Pathophysiology ...	102
Clinical Features ...	102
Location ...	102
Diagnosis ...	102
Gastric Ulcer: Management ...	103
Treatment and Follow-Up ...	103
Gastric Ulcer: Helicobacter pylori ...	104
Tests for Detection of Helicobacter pylori ...	104
Mass, Tumor, Malignancy: Overview ...	105
Classification ...	105
Role of Endoscopy ...	105
Synopsis ...	105

- Mass, Tumor, Malignancy: Diagnosis ... **106**
 Extrinsic Indentation ... 106
- Mass, Tumor, Malignancy: Intramural Tumors ... **107**
 Classification ... 107
 Diagnosis ... 107
 Management Strategy ... 107
- Polypoid Lesions: Benign Tumors ... **108**
 Definition ... 108
 Classification of Benign Gastric Tumors ... 108
 Frequency ... 108
 Diagnosis ... 108
- Polypoid Lesions: Differential Diagnostic Criteria ... **109**
- Polypoid Lesions: Elster Glandular Cysts and Hyperplastic Polyps ... **110**
 Elster Glandular Cysts ... 110
 Hyperplastic Polyps ... 110
- Polypoid Lesions: Focal Hyperplasia and Chronic Erosions ... **111**
 Focal Hyperplasia ... 111
 Chronic Erosions ... 111
- Polypoid Lesions: Adenoma and Rare Findings ... **112**
 Adenoma ... 112
 Heterotopic Brunner Glands ... 112
 Carcinoid ... 112
 Heterotopic Pancreatic Tissue ... 112
 Peutz-Jeghers Syndrome ... 112
- Polypoid Lesions: Management ... **113**
 Treatment and Follow-Up ... 113
- Malignant Diseases of the Stomach:
 Gastric Carcinoma, Early Carcinoma ... **114**
 Gastric Carcinoma ... 114
 Early Carcinoma ... 114
- Malignant Diseases of the Stomach:
 Advanced Gastric Carcinoma ... **115**
 Classification ... 115
- Malignant Diseases of the Stomach:
 Diagnosis of Gastric Carcinoma ... **116**
 Diagnosis ... 116
 Treatment ... 116
- Malignant Diseases of the Stomach:
 Gastric Lymphoma ... **117**
 Clinical Aspects ... 117
 Diagnosis ... 117
- Malignant Diseases of the Stomach:
 Gastric Lymphoma, Treatment ... **118**
 Stages and Treatment Options ... 118
- Portal Hypertension and Hypertensive Gastropathy:
 Clinical Aspects ... **119**
 Causes and Findings ... 119
 Treatment ... 119
- Portal Hypertension and Hypertensive Gastropathy:
 Diagnosis ... **120**
- The Operated Stomach ... **121**
 Special Considerations ... 121
 Systematic Examination ... 121
- The Operated Stomach:
 Endoscopically Identifiable Lesions and Diseases ... **122**
 Alkaline Reflux Gastropathy ... 122
 Reflux Esophagitis ... 122
 Stenoses ... 122
 Ulcers ... 122
- Suture Granuloma ... 122
 Bezoars ... 122
 Gastric Remnant Carcinoma ... 122
 Recurrent Carcinoma ... 122
- Total Gastrectomy ... **123**
- Partial Gastrectomy: Types and Findings ... **124**
 Types ... 124
 Endoscopic Appearance ... 124
- Partial Gastrectomy: Examination ... **125**
- Vagotomy and Fundoplication ... **126**
 Vagotomy and Pyloroplasty ... 126
 Endoscopic Appearance ... 126
 Fundoplication ... 126
 Endoscopic Appearance ... 126
- Angiodysplasias ... **127**
 Definition ... 127
 Diagnosis ... 127
- Diverticula, Abnormal Gastric Contents ... **128**
 Diverticula ... 128
 Abnormal Gastric Contents ... 128
- Miscellaneous ... **129**

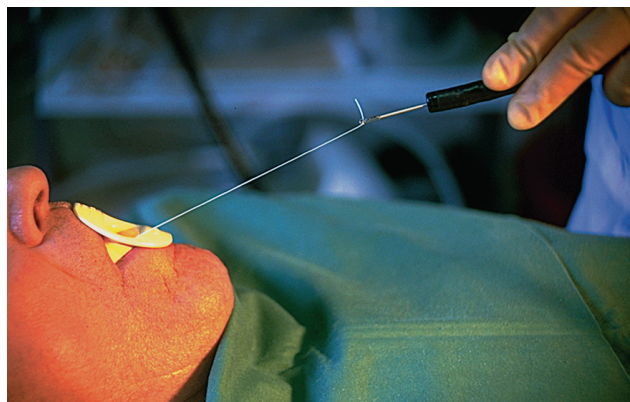


3.3 Pathological Findings: Duodenum ... 130



- Overview of Pathological Findings in the Duodenum ... **132**
- Duodenal Ulcer: Clinical Features ... **133**
 Definition and Causes ... 133
 Clinical Aspects ... 133
 Location ... 133
- Duodenal Ulcer: Diagnosis and Treatment ... **134**
 Diagnosis ... 134
 Treatment and Follow-Up ... 134
- Duodenal Ulcer: Complications ... **135**
 Bleeding, Penetration, and Perforation ... 135
- Bulbitis ... **136**
 Cause ... 136
 Diagnosis ... 136

Polypoid Lesions in the Duodenum ...	137
Classification ...	137
Polypoid Lesions in the Duodenum: Diagnosis ...	138
Sprue, Crohn Disease, and Whipple Disease ...	139
Sprue ...	139
Diagnosis ...	139
Crohn Disease ...	139
Whipple Disease ...	139
Duodenal Diverticula ...	140
Clinical Aspects ...	140
Location ...	140
Diagnosis ...	140
Duodenal Changes Associated with Diseases in Adjacent Organs ...	141
Adjacent Organs ...	141



4 Interventional Procedures and Extended Endoscopic Examination Methods ... 142



Overview of Interventional Endoscopy ...	144
Upper Gastrointestinal Bleeding: Incidence and Signs ...	145
Incidence ...	145
Causes ...	145
Symptoms ...	145
Upper Gastrointestinal Bleeding: Primary Treatment ...	146
Hemodynamic Stabilization ...	146
Maintaining Adequate Respiration ...	146
Identify the Source of Bleeding and Stop the Bleeding ...	146
Bleeding Esophageal Varices and Fundic Varices: Medications and Tubes ...	147
Treatment Methods ...	147
Pharmacological Therapy of Bleeding Esophageal Varices ...	147
Balloon Tamponade ...	147
Bleeding Esophageal Varices: Sclerotherapy ...	148
Endoscopic Treatments ...	148
Sclerotherapy with Polidocanol (Ethoxysclerol) ...	148
Bleeding Esophageal Varices: Banding ...	149
Sclerotherapy of Fundic Varices, TIPS, and Operative Treatment ...	150
Transjugular Intrahepatic Portosystemic Shunt (TIPS) ...	150
Operative Treatment ...	150

Bleeding Ulcers: Nonoperative Therapies ...	151
Incidence and Symptoms ...	151
Nonoperative Treatment Methods ...	151
Indications for Endoscopic Treatment ...	151
Bleeding Ulcers: Forrest Classification ...	152
Bleeding Ulcers: Pharmacological Therapy and Injection Techniques ...	153
Pharmacological Therapy of Bleeding Ulcers ...	153
Endoscopic Techniques ...	153
Injection Therapy ...	153
Bleeding Ulcers: Hemoclip Application and Thermal Methods ...	154
Hemoclip Application ...	154
Thermal Methods ...	154
Bleeding Ulcers: Management after Primary Hemostasis and in Special Cases ...	155
Management after Primary Hemostasis ...	155
Hemostasis of a Mallory–Weiss Lesion ...	155
Hemostasis of a Bleeding Dieulafoy Ulcer ...	155
Hemostasis in Hemorrhagic Gastritis ...	155
Specimen Collection ...	156
Biopsy ...	156
Brush Cytology ...	156
Fluid Sampling ...	156
Endoscopic Treatment of Precancerous Lesions and Early Carcinoma ...	157
Open Resection ...	157
Endoscopic Treatments ...	157
Polypectomy ...	157
Endoscopic Mucosectomy ...	157
Photodynamic Therapy ...	157
Foreign Body Removal ...	158
Incidence and Location ...	158
Symptoms ...	158
Rules for Management ...	158
Foreign Body Removal: Types of Objects Swallowed ...	159
Coins ...	159
Marbles ...	159
Batteries ...	159
Pieces of Meat ...	159
Partial Dentures ...	159
Needles, Toothpicks ...	159
Foreign Bodies with a Hole ...	159
Percutaneous Endoscopic Gastronomy (PEG) Bumper ...	159
Condoms Containing Narcotics ...	159
PEG Placement: Principle, Indications, and Contraindications ...	160
Principle ...	160
PEG Tubes ...	160
Alternative Methods of Tube Placement ...	160
Indications ...	160
Contraindications ...	160
Informed Consent ...	160
Complications ...	160
Preparations ...	160
Aftercare ...	160
PEG Placement: Technique (1) ...	161
PEG Placement: Technique (2) ...	162
PEG Placement: Technique (3) ...	163

PEG Placement: Technique (4) ... **164**

Duodenal Tube: Insertion through a PEG ... **165**

PEJ, Special Cases, and Complications during Tube Placement ... **166**

Removal of PEG Tube, Placement of Duodenal Tube ... **167**

 PEG Tube Removal ... 167

 Placement of a Duodenal Tube ... 167

Duodenal Tube Placement: Technique (1) ... **168**

Duodenal Tube Placement: Technique (2) ... **169**

Duodenal Tube Placement: Technique (3) ... **170**

Upper Gastrointestinal Stenoses, Malignant Strictures ... **171**

 Causes and Sites of Occurrence ... 171

 Treatment Options ... 171

 Malignant Strictures ... 171

 Esophageal Carcinoma ... 171

 Bronchial Carcinoma ... 171

Benign Stenoses ... **172**

 Peptic Esophageal Stricture ... 172

 Gastric Outlet Stricture ... 172

 Corrosive Ingestion ... 172

 Radiation ... 172

 Achalasia ... 172

 Fundoplication ... 172

 Anastomotic Stenosis ... 172

 Banding and Sclerotherapy of Varices ... 172

Upper Gastrointestinal Stenoses: Dilation Methods ... **173**

 Bougie Dilation ... 173

 Balloon Dilation ... 173

Upper Gastrointestinal Stenoses: Incision, Self-Expanding Stents ... **174**

 Incision of Strictures ... 174

 Self-Expanding Stents ... 174

Upper Gastrointestinal Stenoses: Intubation, Laser Treatment ... **175**

 Intubation ... 175

 Laser Treatment ... 175

Upper Gastrointestinal Stenoses: Coagulation and Botulinum Toxin ... **176**

 Argon Plasma Coagulation ... 176

 Injection of Botulinum Toxin ... 176

Chromoendoscopy: Lugol Solution ... **177**

 Definition and Stains ... 177

 Lugol Solution ... 177

Chromoendoscopy: Methylene Blue ... **178**

 Methylene Blue and Barrett Epithelium ... 178

Chromoendoscopy: Indigo Carmine, Uses of Vital Stains ... **179**

 Indigo Carmine ... 179

 Possible Uses of Vital Stains in the Upper Gastrointestinal Tract ... 179

Fluorescent Endoscopy and Magnification Endoscopy ... **180**

 Principle of Fluorescent Endoscopy ... 180

 Magnification Endoscopy ... 180

 Fluorescent Endoscopy with 5-ALA ... 180

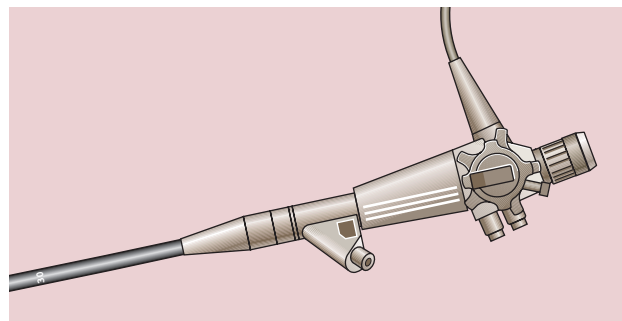
Enteroscopy ... **181**

 Sonde Enteroscopy ... 181

 Push Enteroscopy ... 181

 Intraoperative Enteroscopy ... 181

 Capsule Endoscopy ... 181



Appendix Subject Index ... **182**

 Systematic Endoscopic Examination ... **184**

 Location of Abnormalities ... **185**

 Characterization of Abnormal Findings ... **186**

Subject Index ... **189**